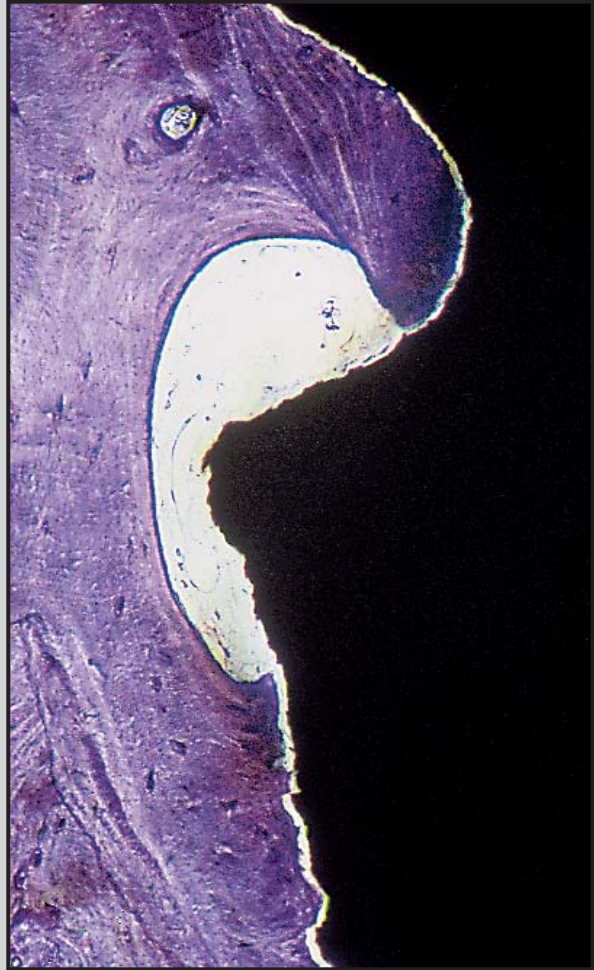
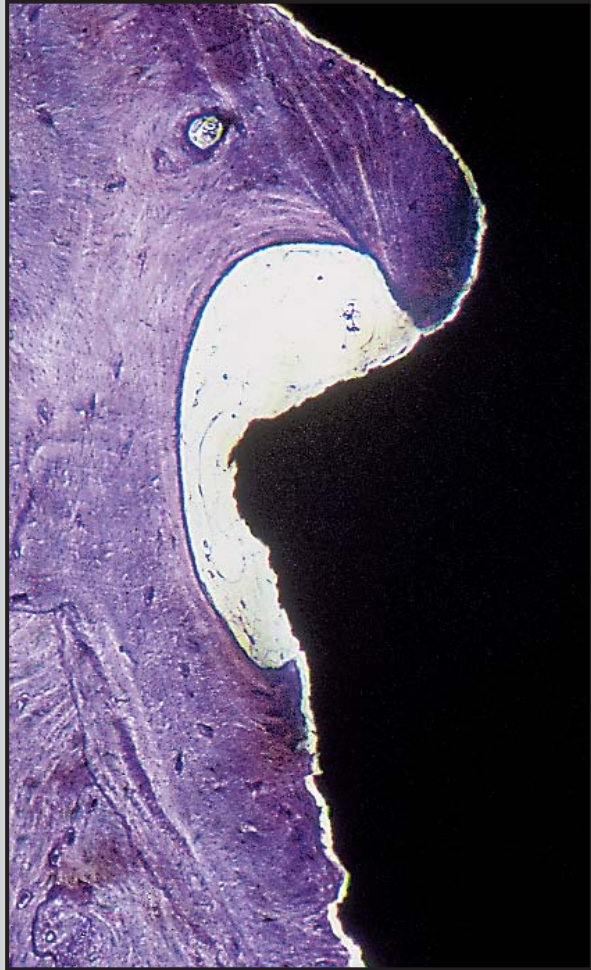
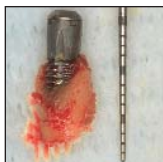

Histologic Analysis of a Failing Three-Part Dental Implant: A Human Case Report



Luca Landi, DDS, CAGS*

Paolo Francesco Manicone, DDS**

Stefano Piccinelli, DDS*

Roberto Raia, DDS*

Two failing implants were removed for prosthetic reasons from the maxilla of a 60-year-old woman. The implants were clinically immobile but presented clear signs of peri-implant mucositis and bone destruction. One of the two implants was harvested together with the surrounding bone and analyzed histologically. The implant was threaded and consisted of three distinct components screwed together in a telescopic fashion. Histologically, bone loss reached the fourth thread, while apical to the fourth thread, osseointegration between the host bone and the implant surface was recognizable. The implant parts were not completely seated into each other, and the resulting gap was colonized by host bone. Newly formed alveolar bone penetrated deep into the implant body cavity and appeared similar in nature to the alveolar bone surrounding the implant. Histologic findings are discussed in reference to the ability of such an implant to withstand biomechanical loading over time. (Int J Periodontics Restorative Dent 2005;25:615–621.)

*Private Practice, Studio di Odontoiatria Ricostruttiva, Rome, Italy.

**Private Practice, Studio di Odontoiatria Ricostruttiva and Visiting Professor, Catholic University of Sacred Heart, Rome, Italy.

Correspondence to: Dr Luca Landi, c/o Studio di Odontoiatria Ricostruttiva, via della Balduina 114, 00136 Rome, Italy; fax: +39-6-35403508; e-mail: studio.ric@tin.it.

Modern implant dentistry has its basis in the scientific evidence of osseointegration provided by Brånemark and his group in 1969.¹ Their work was based on the use of root-form machined titanium implants that, once placed atraumatically into jawbone, became osseointegrated. In the 1970s in Switzerland, the International Team for Implantology (ITI; Institut Straumann) developed a nonsubmerged plasma spray-coated implant that differed from the Brånemark System (Nobel Biocare), but showed similar histologic and clinical success.² Since then, most other manufacturers have designed implant systems that are similar to the original Brånemark System, introducing surface and design modifications in the attempt to improve success and predictability.³ For decades, however, extensive longitudinal data have been published for only the two original implant systems (Nobel Biocare and ITI).⁴ The number of implant manufacturers is increasing rapidly, making the selection of an implant system a difficult task for clinicians. However, many

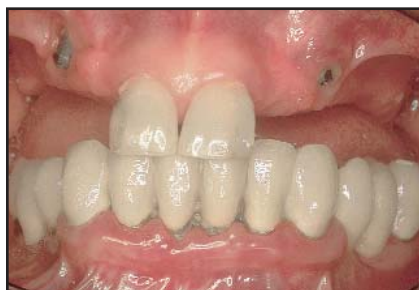

Fig 1 Clinical view of the patient at the time of initial consult. Note the buccal implant positioning, with soft tissue dehiscence particularly evident at the maxillary left canine.

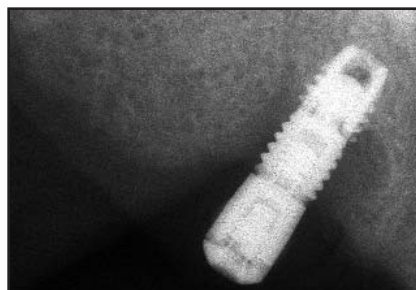


Fig 2a The maxillary right canine implant. Bowl-like peri-implant bone loss is radiographically detectable. It is also possible to observe the original design of the implant. The coronal part is constituted by a smooth collar that is screwed into a threaded middle part. The middle threaded part is then screwed into the apical part, which is threaded and tapered.

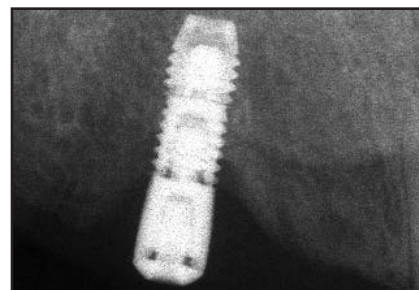


Fig 2b The left canine implant. Less advanced crestal bone loss is evident around the implant. The bony defect reached the fourth thread of the implant, but no peri-implant radiolucency can be seen along the implant body.

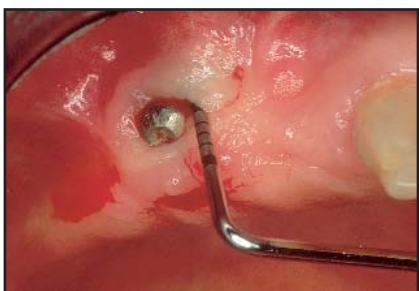

Fig 3 Probing at the right canine implant. The probing depth is 10 mm buccally. Upon probing, bleeding and drainage of exudate could be seen.

implant systems lack appropriate documentation, and it can be difficult to evaluate their performance in a clinical setting.⁴

In this brief case report we provide clinical and histologic documentation of two failing implants retrieved from a patient 2 years after their placement. It is worth noticing that these implants did not resemble any of the implant systems for which there is published documentation available.^{5,6} We also attempt to speculate on the biologic and biomechanical characteristics of this particular type of three-part implant.

Case report

A 60-year-old female patient in good medical condition presented in our clinic complaining of pain during chewing underneath the existing maxillary removable partial denture. Clinically, two implants, not connected to the removable denture, were present in the positions of the maxillary right and left canines (Fig 1). We were unable to obtain any information regarding the implant manufacturer or the patient's past dental history. Radiographically, the implants appeared to be root-form

threaded screws consisting of three parts (Figs 2a and 2b). The two most apical components were threaded, while the coronal component was smooth. Both implants presented with a clearly recognizable bowl-like area of crestal bone loss; however, the bone defect was more advanced at the implant in the maxillary right canine position than at the contralateral implant. Clinically, the implants were characterized by the presence of buccal soft tissue dehiscence, with signs of inflammation of the peri-implant mucosa. The peri-implant area was very tender and

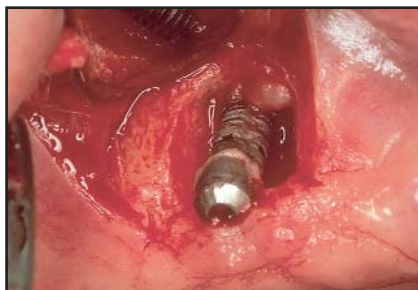

Fig 4 A mucoperiosteal trapezoidal flap is raised at the right canine implant. The granulation tissue is removed. Note the advanced bone resorption circumferentially and the contamination of the implant surface by bacterial plaque. The implant was clinically immobile.

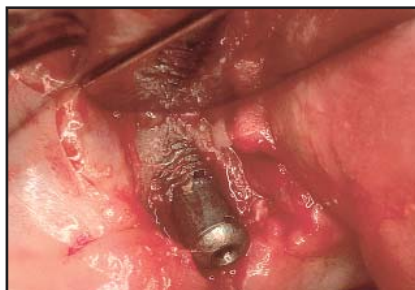

Fig 5 The left canine implant after flap elevation. A bone dehiscence reaching the fourth thread of the implant confirmed the radiographic evidence shown in Fig 2b.

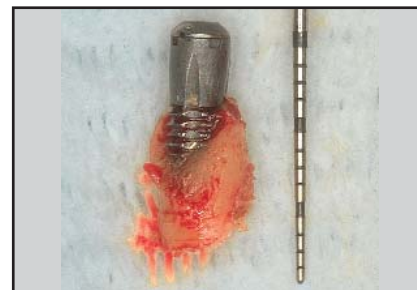


Fig 6 Block specimen of the left canine implant after harvesting together with surrounding bone. It is possible to observe the bone dehiscence buccally.

bled easily upon light palpation and probing. Peri-implant probing around the right canine implant showed a 10-mm pocket depth (Fig 3), while the left canine implant had a probing depth of 6 mm on the buccal side. Nevertheless, both implants were clinically immobile. According to the patient, the implants had been placed about 2 years before in a submerged fashion. The implants had never been surgically uncovered and connected prosthetically, but they had been exposed to the oral cavity, probably because of tissue compression and friction from the removable partial denture. Because of the unfavorable buccal position and direction of the implants and the

advanced peri-implant bone loss, the implants were removed and the patient was provided with a new and well-fitting complete denture. The patient gave her written consent to have the implants removed.

Implant harvesting

The same approach was used to remove both implants. The implant in the left canine site was harvested and processed for histologic analysis. Following administration of local anesthesia (Ultracain D-S, Hoechst), a buccal trapezoidal mucoperiosteal flap was raised and the implant was exposed. A deep bowl-like circum-

ferential defect was present around the right canine implant (Fig 4). At the left canine, the coronal smooth part and the four most coronal threads beyond the smooth portion of the implant were exposed buccally (Fig 5). At this point, the implants and the attached surrounding bone were harvested with a 4-mm-diameter trephine bur under copious irrigation. The left canine implant was harvested intact (Fig 6). The block specimen was rinsed with sterile water and immediately immersed in a 10% paraformaldehyde fixation solution. The surgical socket was filled with a collagen sponge (Spongostan Dental) and the flap was sutured with silk to achieve primary closure.

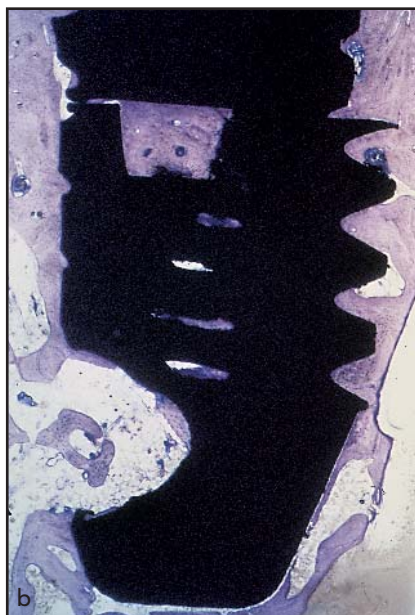

Fig 7 Low-power views of the histologic preparation. The implant design, as it has been described radiographically, is evident. (a) Coronal portion of the implant, with threads that are no longer surrounded by bone. (b) Apical portion of the implant. Good bone-to-implant contact seems to have been established at this magnification (toluidine blue; original magnification $\times 40$).

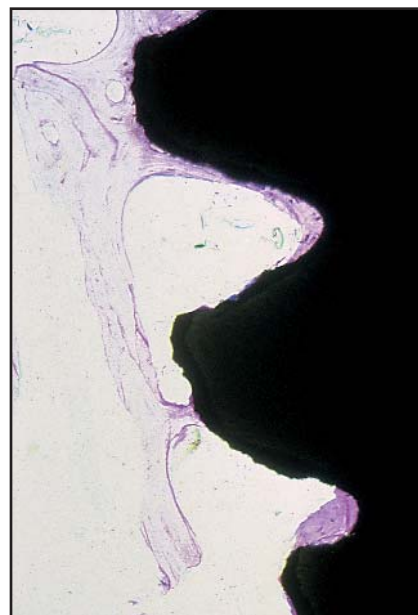


Fig 8 High-power view of the implant threads. The tips of the threads are rather blunted and the surface appears irregular (toluidine blue; original magnification $\times 200$).

Histologic procedure

After fixation, the specimen was further dehydrated in an ascending series of alcohols and then embedded in methylmethacrylate resin (Technovit 7200, Kulzer). After polymerization, the biopsy was processed as for undecalcified specimens according to the technique described by Donath and Breuner.⁷ The specimen was sectioned longitudinally with an Exakt sawing machine to obtain sections of about 150 μm . The sections were then ground to a thickness of about 50 μm . Three sections were obtained, mounted on a glass slide, stained with toluidine blue, and viewed under light microscopy (Zeiss).

Histologic findings

At low-power magnification, it was possible to clearly view the implant design. The implant consisted of three components screwed into each other (Fig 7). The central and apical parts of the implant were threaded and lightly tapered toward the apical zone. The tips of the threads appeared to be rather blunted and irregular (Fig 8). The coronal section of the implant consisted of a long smooth collar screwed into the middle implant component. Bone loss at the most coronal area was visible. The alveolar bone loss stopped at the level of the fourth thread (see Fig 7a). At a higher magnification, the rela-

tionship between the bone and the implant surface could be seen to be characterized by a rather homogenous microgap along the entire perimeter of the implant (Fig 9). This very thin, homogenous gap accurately reproduced the implant surface topography. The absence of any fibrous tissue or staining between implant and bone, along with the clinical stability of the implant at the time of harvesting, led us to consider this, in accordance with others,⁸ as an artifact of the histologic manipulation of the specimen rather than a lack of osseointegration. The peri-implant alveolar bone was mature and lamellar in nature, with osteocytes populating the visible lacunae and

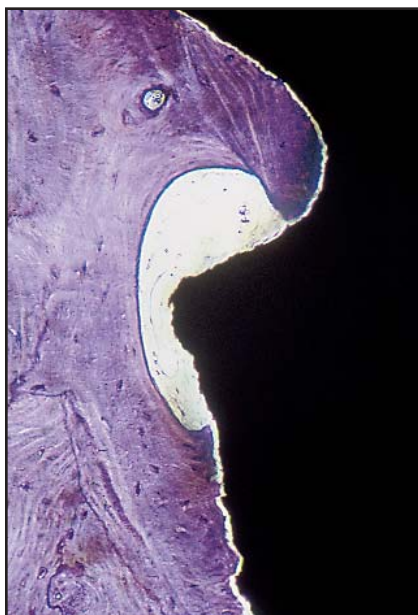


Fig 9 (left) High-power view of the bone-to-implant contact. A marrow space faces the tip of a thread. A gap between the alveolar bone and the implant surface is evident and may be interpreted as an artifact of histologic processing. Note the perfect correspondence between the implant surface and the bone profile (toluidine blue; original magnification $\times 200$).

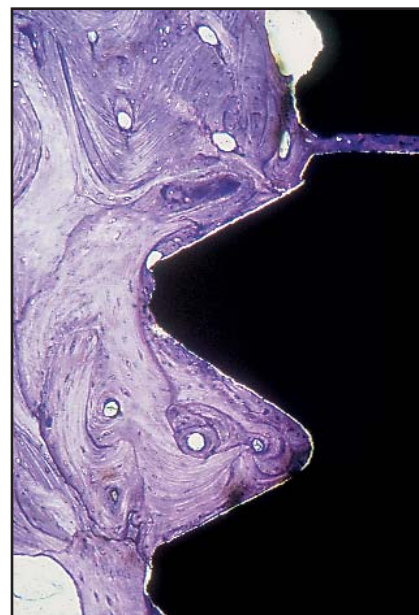
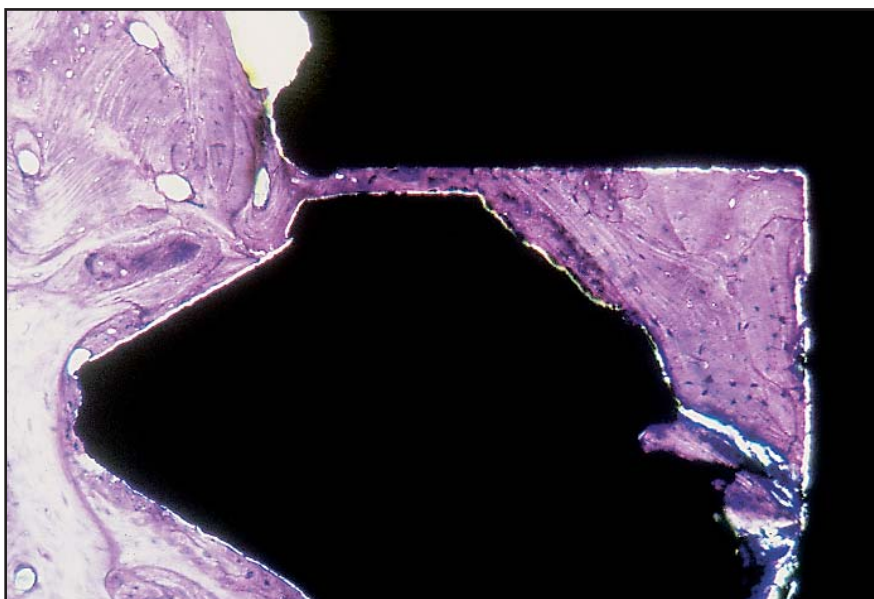


Fig 10 (right) Bone-to-implant contact is rather homogenous along the entire implant perimeter. The alveolar bone appears highly haversian in nature. Lamellation and secondary osteons are visible in the area between the implant threads (toluidine blue; original magnification $\times 100$).

Fig 11 Area of discrepancy between the middle and apical implant components. Alveolar bone is creeping through the gap to reach the implant cavity. Newly formed bone in the implant cavity shows the same histologic characteristics as the surrounding alveolar bone (toluidine blue; original magnification $\times 200$).



very limited marrow spaces. Secondary osteons could also be seen around the peri-implant bone tissue (Fig 10). Interestingly, the two most apical implant components

were not completely seated into each other. The resulting gap was partially obliterated by host bone that migrated into the implant body (Fig 11). The bone created in this

kind of experimental titanium chamber was similar in nature to the bone surrounding the implant periphery.

Discussion

Implant composition, design, macro- and micro-irregularities, and surface topography have been indicated as factors that may influence osseointegration. Titanium or titanium alloys may be considered bioinert materials that allow bone apposition on their surface and lead to contact osteogenesis.⁹ Our retrieved specimen confirms that titanium or titanium alloys may lead to osseointegration, regardless of implant design. Close apposition of lamellar bone was evident along the entire perimeter of the implant. The implants were clinically immobile, but in both cases an advanced bone resorption pattern could be seen. Criteria for implant success have been continuously revised since the 1978 NIH Harvard consensus conference on implant success.¹⁰ It is now well accepted that an absence of clinical mobility alone cannot be considered sufficient as a criterion for success. Restorability, degree of bone loss, satisfactory peri-implant probing depths, and absence of symptoms must also be considered in determining the success or failure of an implant.¹¹ Therefore, according to these criteria, the present implants must be considered failed.

Spontaneous uncovering of submerged implants has been shown to be accompanied by increasing crestal bone loss.¹² In the present case, compression induced by a complete denture may have initiated crestal bone loss and then set the stage for bacterial plaque accumulation. This may have led to the

appearance of a peri-implant lesion.¹³ Interestingly, we noted that implant parts failed to achieve a perfect fit. The gaps between the implant components were filled by lamellar bone and marrow spaces. Newly formed bone penetrated inside the implant body cavity through the microgap. This observation deserves some consideration. A precise fit of prosthetic restorations is essential to maintain prosthetic stability and osseointegration over time. Misfitting components may cause abutment fracture. However, an even more detrimental effect of component misfit is a non-physiologic distribution of loading stresses into the surrounding bone.^{14,15} In the present case, the implants, although never prosthetically connected, may have received some load, because they were uncovered and overlaid by a complete denture.

It can be speculated what might have happened once abutment connection and occlusal function were established. Abutment connection and loading with occlusal forces may have led to fatigue in the areas of the component connections. One of the most common mechanical complications in implant treatment is loosening of the prosthetic abutments.^{16,17} In this case, the risk of such an event was increased by the presence of an additional screw connecting the implant parts. However, in this case, the risk of mechanical failure would be even more detrimental, affecting not only the connection between the implant and the abutment but involving the implant body itself.

Other factors that may be important in leading to implant fracture include the grade of titanium used, implant diameter, implant design, characteristics of the abutment connection, crown-to-implant ratio, the presence of cantilevers, and the conditions of loading as related to the opposing arch.¹⁸ However, if the implant selected, as in this case, holds in its original design such a high degree of inaccuracy so as to affect implant stability and ultimately induce treatment failure, even the histologic evidence of osseointegration should not be viewed as satisfactory. The American Dental Association guidelines for accreditation of dental implants are very strict, and each clinician should determine whether their chosen implant system meets those criteria.¹⁹ Fiorellini and coworkers recently stated that "Unfortunately, many of the remaining dental implant systems have relied on the concept of having substantial equivalence to prior Nobel Biocare studies. Consequently, several implant systems do not have published data related to efficacy, including life table analysis of specific indications."^{4p130} New implant designs released into the market that not only lack any evidence of documented safety and efficacy but also present with major changes in design or protocol so that no claim of equivalence may be made with other documented implants should be considered with caution for clinical use.

Acknowledgments

The authors would like to thank Mr Ercole Mongardini and Mr Ezio Bassotti, laboratory technicians at the Catholic University of Sacred Heart Dental Clinic, Rome, for the histologic preparation of the specimens.

References

1. Brånemark P-I, Adell R, Breine U, Hansson BO, Lindstrom J, Ohlsson A. Intraosseous anchorage of dental prostheses. 1. Experimental studies. *Scand J Plast Reconstr Surg* 1969;3:81-100.
2. Schroeder A, van der Zypen E, Stich H, Sutter F. The reaction of bone, connective tissue and epithelium to endosteal implants with sprayed titanium surfaces. *J Maxillofac Surg* 1981;9:15-25.
3. Sykaras N, Iacopino AM, Marker VA, Triplett RG, Woody RD. Implant materials, designs, and surface topographies: Their effect on osseointegration. A literature review. *Int J Oral Maxillofac Implants* 2000;15:675-690.
4. Fiorellini JP, Martuscelli G, Weber HP. Longitudinal studies of implant systems. *Periodontol 2000* 1998;17:125-131.
5. Binion PP. Implants and components: Entering the new millennium. *Int J Oral Maxillofac Implants* 2000;15:76-94.
6. Sahiwal IG, Ronald DW, Benson BW, Guillen GE. Radiographic identification of threaded endosseous dental implants. *J Prosthet Dent* 2002;87:563-577.
7. Donath K, Breuner G. A method for the study of undecalcified bone and teeth with attached soft tissues. *J Oral Pathol* 1982;11:318-326.
8. Albrektsson T, Sennerby L. Direct bone anchorage of oral implants: Clinical and experimental considerations of the concept of osseointegration. *Int J Prosthodont* 1990;3:30-41.
9. Kasemo B, Lausmaa J. Metal selection and surface characteristics. In: Brånemark P-I, Zarb GA, Albrektsson T (eds). *Tissue-Integrated Prostheses: Osseointegration in Clinical Dentistry*. Chicago: Quintessence, 1985:99-116.
10. Recommendations. Definition of success and efficacy. In: Schnitman PA, Schulman LB (eds). *Dental Implants, Benefit and Risk: Proceedings of an NIH-Harvard Consensus Development Conference Held at Harvard School of Dental Medicine, June 13-14, 1978*. Bethesda, MD: U.S. Department of Health and Human Services, Public Health Service, National Institutes of Health, 1980:329-330.
11. Albrektsson T, Zarb G, Worthington P, Ericsson B. Long-term efficacy of currently used dental implants: A review and proposed criteria of success. *Int J Oral Maxillofac Implants* 1986;1:11-25.
12. Toljanic JA, Banakis ML, Willes LAK, Graham L. Soft tissue exposure of endosseous implants between stage I and stage II surgery as potential indicator of early crestal bone loss. *Int J Oral Maxillofac Implants* 1999;14:436-441.
13. Mombelli A, Lang NP. The diagnosis and treatment of peri-implantitis. *Periodontol* 2000 1998;17:63-76.
14. Brunski JB, Skalak R. Biomechanics of osseointegration and dental prostheses. In: Naert I, van Steenberghe D, Worthington P (eds). *Osseointegration in Oral Rehabilitation*. Chicago: Quintessence, 1993:133-156.
15. Rangert B, Krogh PHJ, Langer B, Van Roekel N. Bending overload and implant fracture: A retrospective clinical analysis. *Int J Oral Maxillofac Implants* 1995;10:326-334 [erratum 1996;11:575].
16. Ekfeldt A, Carlsson GE, Borjesson G. Clinical evaluation of single-tooth restorations supported by osseointegrated implants: A retrospective study. *Int J Oral Maxillofac Implants* 1994;9:179-183.
17. Sakaguchi RL, Borgensen SE. Nonlinear contact analysis of preload in dental implants screws. *Int J Oral Maxillofac Implants* 1995;10:295-302.
18. Eckert SE, Meraw SJ, Cal E, Ow RK. Analysis of incidence and associated factors with fractured implants: A retrospective study. *Int J Oral Maxillofac Implants* 2000;15:662-667.
19. Weber H, Fiorellini J, Jeffcoat M. Placement in existing bone. Proceedings from the 1996 Joint Symposium on Clinical Trial Design and Analysis in Periodontics. *Ann Periodontol* 1997;2:315-328.