


Marginal soft tissue recession after lateral guided bone regeneration at implant site: A long-term study with at least 5 years of loading

Francesco Cairo¹  | Michele Nieri¹ | Raffaele Cavalcanti² | Luca Landi³ | Antonio Rupe⁴ | Nicola Marco Sforza⁵ | Riccardo Pace¹ | Luigi Barbato¹

¹Research Unit in Periodontology and Periodontal Medicine, Department of Clinical and Experimental Medicine, University of Florence, Florence, Italy

²Private Practice, Bari, Italy

³Private Practice, Roma-Verona, Italy

⁴Private Practice, Benevento, Italy

⁵Private Practice, Bologna, Italy

Correspondence

Francesco Cairo, via fra' Giovanni Angelico 51, 50121, Florence, Italy.
Email: francesco.cairo@unifi.it

Funding information

Geistlich Pharma AG

Abstract

Background/aim: This study evaluated marginal soft tissue recession at implants with simultaneous lateral guided bone regeneration (GBR), at least five years after prosthetic loading.

Material and methods: Patients treated with GBR at the time of implant placement and adherent to supportive periodontal therapy (SPT) program with at least 5 years of follow-up were re-examined in 5 clinical centers. At the last follow-up, clinical and radiographic data on peri-implant hard and soft tissue were collected. Multilevel analysis considering center, patient, and implant (brand, length, diameter, position) was performed.

Results: A total of 96 patients and 195 augmented implants were included. The mean duration of SPT was 8.3 ± 3.1 years, while mean recall frequency was 4.5 ± 1.3 months. Sixty-five (33%) implants received soft tissue graft before prosthetic delivery. Twenty-one (11%) implants developed biological complications during the follow-up. No implant failure was reported. Mean difference in bone levels (Δ BL) was -0.7 ± 0.9 mm, while mean difference in keratinized tissue (Δ KT) was -0.4 ± 0.9 mm. Eighty-five (44%) implants showed recession (REC) of soft tissue margin (mean 0.6 ± 0.8 mm). The presence of REC was associated with use of non-resorbable membrane ($p < .0001$) and wider implant diameter ($p = .0305$), while use of soft tissue graft significantly predicted higher stability of peri-implant mucosal margin ($p = .0003$).

Conclusion: Peri-implant mucosal recession is a common feature 5 years after lateral GBR. The risk of recession may be reduced using GBR with resorbable membranes, small diameter implants, and soft tissue grafting before prosthetic treatment.

KEYWORDS

dental implant, gingival recession, guided bone regeneration, long-term

1 | INTRODUCTION

Long-term studies showed that dental implants have high survival rate when a specific supportive periodontal care program is performed (Balshi, Wolfinger, Stein, & Balshi, 2015; Jemt, 2018). At time of implant installation, bone deficiency may complicate a prosthetically driven fixture positioning, thus hindering final outcomes. In these conditions, hard tissue reconstruction should be considered (Lutz, Neukam, Simion, & Schmitt, 2015). Guided bone regeneration (GBR) is a predictable method to reconstruct bony defect at implant site (Benic & Hämmerle, 2014). In case of horizontal defect, GBR could be performed before (Naenni, Lim, Papageorgiou, & Hämmerle, 2019) or at the time of implant placement (Merli et al., 2016; Thoma, Bienz, Figuero, Jung, & Sanz-Martín, 2019).

Among the proposed regenerative techniques, GBR using resorbable collagen membrane and deproteinized bovine bone mineral (DBBM¹) is a predictable approach in terms of dehiscence resolution (Merli et al., 2016). On the other hand, final soft tissue appearance is a critical issue for final patient satisfaction (Bonde, Stokholm, Schou, & Isidor, 2013), and very often, soft tissue augmentation procedure is advocated in order to potentially improve the final stability of peri-implant mucosal margin (Cairo et al., 2019; Cairo, Pagliaro, & Nieri, 2008).

Data on soft tissue level after implant placement with GBR have been reported in studies with short-term follow-up (Sanz-Sánchez et al., 2018; Thoma et al., 2019), while possible stability of peri-implant mucosal margin is not usually described in long-term studies (Lutz et al., 2015).

The aim of this long-term, multicenter study was to evaluate changes at soft and hard peri-implant tissues at implants with simultaneous lateral GBR, at least five years after prosthetic loading.

2 | MATERIAL AND METHODS

2.1 | Study design and setting

This study was reported according to STROBE guideline (Vandenbroucke et al., 2007). This was a retrospective analysis at least 5 years after final prosthetic delivery in patients treated with dental implants and simultaneous GBR. Five clinical centers were involved, incorporating expert operators with more than 10 years of clinical experience in dental implants and bone regeneration. Patients were consecutively selected in the single clinical centers according to the entry criteria.

2.2 | Participants and inclusion criteria

The study protocol was approved by University of Florence Ethical Board (Ref. 25379/2018). Informed consent was obtained from all

subjects included in the study. The study was conducted according to the principles outlined in the Declaration of Helsinki on experimentation involving human subjects, as revised in 2000.

Participants consecutively selected and satisfying the following entry criteria were recruited:

- Age \geq 18 years
- Lateral bone augmentation performed at the time of implant placement.
- GBR performed using a resorbable² or non-resorbable membrane³ supported by deproteinized bovine bone mineral (DBBM) and/or autogenous bone (AB) chips.
- Compliance with a supportive periodontal therapy program (SPT) for at least 5 years.
- Available peri-implant parameters and intraoral radiograph at the time of final prosthesis delivery (baseline of the study-T0).

The following exclusion criteria were considered

- GBR before implant placement
- Different hard tissue augmentation procedures performed
- Patients not following a regular SPT

2.3 | Outcomes and data collection

The primary outcome for this study was the change of position of the peri-implant mucosal level (REC) at the buccal aspect between final prosthesis delivery (T0) and last follow-up (T1). Secondary outcomes included mean bone levels and amount of keratinized tissue.

At baseline of the study, the following variables were collected from clinical records at patient and implant level:

2.4 | Patient level at baseline

- gender (M/F)
- smoking habits (Y/N)
- systemic disease/drugs (Y/N)

2.5 | Implant level at baseline

- age for patient at implant level (years)
- implant position (maxilla/mandible; anterior/posterior)
- implant brand
- implant length (mm) and diameter (mm)
- provisional restoration (Y/N)
- type of prosthesis (screw-retained or cemented)

¹Deproteinized bovine bone mineral (DBBM) = Geistlich Bio-Oss®.

²Resorbable membrane = Geistlich Bio-Gide®.

³Non-resorbable membrane = e-PTFE Gore Tex®.

- loading implant condition (immediate, conventional)
- reason for tooth extraction
- type of installation (healed bone, delayed/post extraction)
- bone quality (D1 to D4)
- type of defect (5 classes according to Benic & Hämmerle, 2014)
- type of healing (1 or 2 stages)
- possible soft tissue augmentation before final prosthesis (Y/N)
- probing depth (PD) at implant at six points (mm)
- marginal soft tissue level (MSTL) measured from the top of the abutment (abutment-crown junction) to the soft tissue margin, with positive values representing abutment margin location in supramucosal position. It was assumed that when abutment-crown junction was not visible there was no soft tissue recession.
- keratinized tissue (KT) (mm), as the distance between peri-implant mucosal margin and mucogingival junction position at middle point of the buccal side.

At the final follow-up visit, the following variables were recorded:

2.6 | Patient level at final follow-up

- Duration of SPT/Length of follow-up
- Frequency of SPT
- Full mouth plaque score (FMPS) and full mouth bleeding score (FMBS) (measured at four sites per tooth)

2.7 | Implant level at final follow-up

- PD at six points (mm)
- Marginal soft tissue level (MSTL)
- KT (mm)
- Bleeding on probing (BOP) at implant at six points (Y/N)
- Plaque index at implant at six points (Y/N)

In addition, intraoral radiographs were performed at final follow-up to evaluate peri-implant bone levels. Furthermore, data on biological complications were collected. According to international standards, mucositis was defined as “*Peri-implant mucosal inflammation in the absence of continuous marginal peri-implant bone loss*” (Heitz-Mayfield & Salvi, 2018), while peri-implantitis as “*Plaque-associated pathological condition in tissues around dental implants, characterized by inflammation in the peri-implant mucosa and subsequent progressive loss of supporting bone*” (Berglundh et al., 2018). Data on complication treatments were collected on patient file.

2.8 | Marginal bone level assessment

Bone level change (Δ BL) was considered as the difference between bone levels measured at final follow-up and baseline, using intraoral radiographs obtained applying a long-cone parallel technique with

a Rinn-type film holder at each control. Bone levels were measured on enlarged pictures as the distance in mm between bone crest (BC) at mesial and distal site of the implant using the implant-abutment interface (IA interface) as reference point. The measurements were rated positive when the BC was coronal to IA interface and negative when BC was below the reference point. The mean of mesial and distal measurements at each implant was used.

2.9 | Sample size

Since this was a retrospective analysis, exact sample sizing was not performed. Considering for change in recession an effect size of 1, $\alpha = .002$ (Bonferroni adjustment), a power of 80%, a mean of two implants per patient, and an intraclass correlation coefficient of 0.30, at least 120 implants were considered necessary (considering two balanced groups) in a sample size determination for cluster trial designs (Julious, 2010). Patients were enrolled from those attending SPT program in the clinical centers and fulfilling the inclusion criteria.

2.10 | Quantitative variables and statistical methods

Descriptive statistics using mean and standard deviation for quantitative variables, and frequency and percentage for qualitative variables were performed. For inferential analysis, multilevel models were performed. Primary outcome variable was change in soft tissue recession (REC) as the difference between MSTL at baseline and final follow-up. For change in REC, 3-level models (center, patient, and implant) were performed. Bivariate analyses were conducted, considering every single variable as a predictor variable for change REC. A multilevel, stepwise backward analysis was performed using the significant variables in the bivariate analyses as predictors for change in REC. The level of significance ($p > .05$) was considered as exclusion criteria for the stepwise backward analysis.

3 | RESULTS

An initial sample of 114 patients was initially screened among clinical centers. A total of 18 patients did not agree to participate in the study. Finally, a total of 96 patients (65 women) accounting for 195 implants placed in conjunction with lateral GBR were included in this study. Descriptive statistics are reported in Table 1.

3.1 | Outcomes at patient level

Considering prostheses delivery as baseline, the mean duration of SPT was 100.2 ± 37.4 months [range 60–241], corresponding to 8.3 years, with a mean SPT frequency of 4.5 ± 1.3 months. Eighteen (19%) patients were smokers. FMPS and FMBS at final follow-up were $14.5\% \pm 7.3$ and $12.7\% \pm 5.9$, respectively.

TABLE 1 Cohort description

n° patients	96	
Female/Male	65 (68%) F	31 (32%) M
Systemic disease n (%)	18(19%) Yes	
Smoking n (%)	18 (19%) Yes	
Age (Years)	51.7 ± 9.8; [20 to 77]	
n° implant	195	
Center	n° Patients (n/%)	n° Implants (n/%)
1	21 (22%)	38 (19%)
2	19 (20%)	49 (25%)
3	17 (18%)	29 (15%)
4	17 (18%)	25 (13%)
5	22 (23%)	54 (28%)
Reason for extraction n (%)	Periodontitis 84 (43%)	Other 111 (57%)
Implant brand n (%)	Straumann 101 (52%) 3i 51 (26%) Nobel 32 (16%) Astratech 10 (5%) Winsix 1 (1%)	
Implant length (mm)	10.3 ± 1.6; [7 to 15]	
Implant diameter (mm)	4.0 ± 0.4; [3.25 to 5]	
Bone Quality n (%)	D1 13 (7%); D2 115 (59%); D3 51 (26%); D4 16(8%)	
Experimental site n (%)	Maxilla 122 (63%)	Mandible 73 (37%)
	Anterior 50 (26%)	Posterior 145 (74%)
Type of defect n (%)	Type I	13 (7%)
	Type II	113 (58%)
	Type III	52 (27%)
	Type IV	17 (9%)
Type Installation n (%)	Healed	116 (59%)
	Delayed	59 (30%)
	Post-extractive	20 (10%)
Type of healing n (%)	I stage	53 (27%)
	II stage	142 (73%)
Type of bone graft n (%)	DBBM	124 (64%)
	Autogenous bone	20 (10%)
	Mix	51 (26%)
Type of membrane n (%)	Resorbable CM	168 (86%)
	Non-resorbable	27 (14%)
Soft tissue augmentation n (%)	65 (33%) Yes	
Type of soft tissue augmentation (n %)	CTG	38 (58%)
	XCM	4 (6%)
	Modified roll technique	23 (35%)

(Continues)

TABLE 1 (Continued)

Center	n° Patients (n/%)	n° Implants (n/%)
Provisional prostheses n (%)	172 (88%) Yes	
Loading condition n (%)	Immediate	17 (9%)
	Conventional	178 (91%)
Type restoration n (%)	Screw-retained	78 (40%)
	Cemented	117 (60%)
ΔBL (mm)	−0.7 ± 0.9 [−5.5 to 1.0]	
Mean KT at baseline (mm)	3.3 ± 1.6 [0 to 8]	
Mean KT at F-up (mm)	2.9 ± 1.7 [0 to 9]	
Change in KT (mm)	−0.4 ± 0.9 [−4 to 2]	
Mean MSTL at baseline (mm)	0.1 ± 0.3 [0 to 2]	
Mean MSTL at F-up (mm)	0.6 ± 0.9 [0 to 4]	
Site with REC at F-up n(%)	85 (44%)	
REC (mm)	0.6 ± 0.8 [0 to 4]	
Mean PD at baseline (mm)	2.7 ± 0.8 [1.0 to 4.2]	
Mean PD at F-up (mm)	3.1 ± 0.9 [1.0 to 7.0]	
Change in PD (mm)	0.4 ± 0.8 [−1.7 to 4.3]	
Follow-up (months)	100.2 ± 37.4 [60 to 241]	
Mean interval SPT (months)	4.5 ± 1.3 [1.0 to 6.0]	
FMPS (%)	14.5 ± 7.3 [0 to 35]	
FMBS (%)	12.7 ± 5.9 [3 to 27]	
Mean BoP	0.2 ± 0.3 [0 to 1]	
Mean PI	0.2 ± 0.2 [0 to 1]	
Implant BoP + n (%)	108 (55%) Yes	
Implant PI + n (%)	126 (65%) Yes	
Complication n (%)	21 (11%)	
	11 peri-implantitis	
	8 mucositis	
	2 recession needing treatment	

Abbreviations: BoP, bleeding on probing; CM, collagen matrix; CTG, connective tissue graft; DBBM, demineralized bovine bone matrix; FMBS, full mouth bleeding score; FMPS, full mouth plaque score; KT, keratinized tissue; MSTL, Marginal Soft Tissue Level; PD, probing depth; PI, plaque index; REC, mucosal recession at implant between baseline and follow-up; SPT, supportive periodontal therapy; XCM, xenogenic collagen matrix; ΔBL, mean difference in bone levels measured on intraoral radiograph between baseline and final follow-up.

3.2 | Outcomes at implant level

Regarding GBR procedure, in 168 (86%) cases a resorbable collagen membrane was applied, while in 27 (14%) a non-resorbable membrane was used. In 124 implants (64%), DBBM was used alone under the barrier; in 51 (26%) implants, a mix DBBM/AB was applied, and

in 20 (10%) implants, AB was used alone under membrane. Sixty-five (33%) of the implants received also a soft tissue graft before the final prosthesis. At the final follow-up, soft tissue recession occurred in 85 (44%) of implants. Mean REC from final prosthesis to follow-up was 0.6 ± 0.8 mm [range 0 to 4]. The mean difference in bone levels (Δ BL) was -0.7 ± 0.9 mm [range -5.5 to 1.0], while the mean difference in keratinized tissue (Δ KT) was -0.4 ± 0.9 mm [range -4 to 2].

3.3 | Inferential statistics

Statistical analysis revealed that 3 variables were related to change in REC (Table 2). Results of the multilevel stepwise backward analysis for change in REC between baseline and follow-up were presented in Table 3. Non-resorbable membrane was associated with higher incidence of final REC. The adjusted difference in respect to resorbable membrane was 0.7 mm [95% CI from 0.4 to 1.1 mm; $p < .0001$]. Wider implant diameter was also associated with REC. For each additional mm of implant diameter, the recession worsened by 0.3 mm [95% CI from 0.02 to 0.5 mm; $p = .0305$]. Soft tissue augmentation procedure was associated with less probability of REC and higher stability of peri-implant mucosal margin (Figures 1 and 2). The adjusted difference in respect to no augmentation was -0.4 mm [95% CI from -0.6 to -0.2 ; $p = .0003$].

4 | DISCUSSION

In the last two decades, GBR has been extensively tested in conjunction with dental implants to correct bony dehiscences/fenestrations and/or to increase the thickness of buccal plate (Thoma et al., 2019). In a long-term study on 72 patients and a total of 265 implants, GBR performed using resorbable or non-resorbable membrane achieved a cumulative implant survival rate of 93.2% after 12.5 years of observation (Jung, Fenner, Hämmerle, & Zitzmann, 2013).

In the present multicenter, long-term study a total of 96 patients and 195 implants with regenerated buccal cortical plates were re-examined in 5 clinical centers in Italy, with a mean follow-up of 8.3 years. At the final observation, all implants survived thus confirming that lateral GBR with simultaneous dental implant application is a predictable procedure in modern dentistry (Thoma et al., 2019). This finding supports the use of regeneration in improving buccal cortical plate at implant site in order to promote stability of buccal tissue (Benic, Bernasconi, Jung, & Hämmerle, 2017b; Benic, Ge, et al., 2017). There is also evidence from a single RCT with 18 months of follow-up (Jung et al., 2017), that small dehiscences with spontaneous healing showed higher bone remodeling but no difference for change in mucosal level compared to regenerated sites. On the contrary, implants with a failed GBR and a residual defect >1 mm showed more mucosal recession and bleeding on probing after 4 years of prosthetic loading compared to implants without a residual defect (Schwarz, Sahn, & Becker, 2012).

In the present sample of patients, the incidence of peri-implantitis detected during SPT was limited to 5% of implants. All cases were successfully treated with not surgical/surgical procedures and were clinically stable at the last follow-up. It should be kept in mind, for correct data interpretation, that present outcomes were achieved in specific clinical settings specialized in periodontal and implant treatments. In fact, all treated patients were enrolled in a strict professional supportive periodontal therapy program, with a mean recall of 4.5 months. Final mean values of FMPS and FMBS $< 15\%$ before last professional oral hygiene procedure suggested that patients were highly compliant. These elements may explain the complete implant survival and the very limited number of biological complications, confirming the critical role of periodontal treatment in patients requiring implant application (Ferreira, Silva, Cortelli, Costa, & Costa, 2006; Pijetursson et al., 2012).

The present study showed that at the last follow-up visit, 44% of the implants showed recession (0.6 mm \pm 0.8) of the marginal soft tissue compared with the baseline (Figure 3). Similar findings (mean recession 0.5 mm) were reported in another long-term study (Jung et al., 2013). Multilevel statistical analysis showed that adding soft tissue augmentation was associated with less soft tissue recession with an estimate effect of 0.4 mm. Interestingly, the present study suggested also a similar trend in KT reduction compared with baseline (Δ KT = -0.4 ± 0.9 mm). Comparable results were found in a five-year prospective study reporting higher stability of the soft tissue levels around augmented implants receiving also a soft tissue graft harvested from the palate and placed at healing abutment stage (Hosseini, Worsaae, & Gotfredsen, 2020). In addition, a retrospective analysis showed that adding of CTG on single anterior maxillary implants was associated with better aesthetic outcomes in term of soft tissue contour (Boardman, Darby, & Chen, 2016), while a recent SR reported more recession after 5 years at sites with less than 2 mm of KT at baseline (Iorio-Siciliano, Blasi, Sammartino, Salvi, Sculean, Blasi, Sammartino, Salvi, & Sculean, 2020). Even if no definitive evidence from RCTs is available, soft tissue augmentation procedures around dental implants seem to be promising in improving soft tissue thickness and mucosal level stability (Cairo et al., 2017, 2019).

Multilevel statistical analysis revealed that wider implant diameter was associated with an higher probability of recession at final follow-up, thus confirming that large diameter implant may impair buccal soft tissue stability (Chen, Darby, & Reynolds, 2007; Small & Tarnow, 2000). It could be reasonable to speculate that wider implant may impair bone remodeling after implant installation, leading to a reduced blood support at cancellous and cortical bone with a resorption especially in case of thin buccal plate (Romanos, Delgado-Ruiz, & Sculean, 2019). However, further evidence from prospective trials is mandatory to clarify this issue. Even is not possible to identify a threshold value for implant diameter, a linear association between larger implant diameter and deeper final mucosal recession is reported (Figure 4). Conversely, the possible effect of screw-retained or cemented restorations on the risk of final recession was

TABLE 2 Bivariate analysis for change in REC between baseline and follow-up. Results of the multilevel analysis

Factor	Estimate	Std Err	p value
Male versus Female	0.059	0.151	.70
Systemic disease	0.081	0.178	.65
Smoking	0.009	0.007	.20
Age	0.009	0.007	.20
Extraction Periodontitis	0.239	0.138	.08
Straumann versus Other	-0.046	0.156	.77
Implant length (mm)	-0.062	0.034	.07
Implant diameter (mm)	0.356	0.129	.006
Bone Quality (3,4 vs. 1,2)	-0.294	0.129	.023
Maxilla versus Mandible	-0.103	0.115	.37
Anterior versus Posterior	-0.296	0.124	.017
Defect (III,IV vs. I,II)	0.043	0.115	.71
Installation (Healed vs. Other)	0.073	0.119	.54
Healing (II stage vs. I stage)	0.259	0.171	.13
Bone graft (Autogenous or Mix vs. DBBM)	-0.049	0.147	.74
Membrane (Non-resorbable vs. Resorbable)	0.704	0.180	<.001
Soft tissue augmentation	-0.403	0.122	<.001
Provisional prosthesis	0.227	0.195	.24
Immediate loading	-0.177	0.205	.39
Cemented versus Screw-retained	0.035	0.140	.80
BL at baseline (mm)	-0.071	0.053	.18
KT at baseline (mm)	-0.067	0.037	.07
MSTL at baseline (mm)	0.559	0.242	.021
PD at baseline (mm)	0.059	0.082	.47
Interval SPT (months)	-0.124	0.054	.022
Follow-up (months)	0.003	0.002	.15

Note: Statistically significant values are given in bold.

Abbreviation: Std Err, Standard error.

tested in a bivariate analysis showing no influence of the type of restoration on the clinical outcomes.

The present study showed also that use of resorbable membrane was associated with higher final stability of peri-implant mucosal margin compared with the use of non-resorbable membranes, thus supporting the concept that resorbable membrane could be considered the proper tool for lateral GBR (Chiapasco & Zaniboni, 2009). It could be speculated that the necessary surgical removal of non-resorbable membrane may be associated with higher bone resorption due to the exposure of newly regenerated tissue.

Limits of this study could be related to its retrospective design. Soft tissue augmentation was not randomly allocated but applied after clinical evaluation, and heterogeneity exists in terms of dental implant brands used in the present sample of patients. In addition, the mucosal recession was monitored using abutment-crown junction as reference point without possible stent for measurement standardization. Furthermore, it should be considered that

all treated cases showed a prosthetically driven fixture positioning and standard abutment application but no data regarding fixture angle are available and this might had influenced final recession (Chen et al., 2007). Finally, enclosed patients were treated in private offices focused on periodontal and implant treatments and applying a very strict supportive therapy program. These aspects may reduce the generalizability of the reported outcomes in the clinical practice.

In conclusion, this study suggested that

1. Dental implants placed in conjunction with lateral GBR showed optimal long-term survival under a stringent SPT
2. Soft tissue augmentation procedure before prosthetic treatment was associated with higher stability of peri-implant mucosal margin at the final follow-up compared with not augmented sites
3. Wider implant diameter and the use of non-resorbable membrane increased the risk of mucosal recession in the long term.

TABLE 3 Results of the multilevel stepwise backward analysis for change in REC between baseline and follow-up

Variables	Estimate	Std error	95% CI	<i>p</i> value
Intercept	-0.496	0.494		
Diameter	0.264	0.122	0.025; 0.503	.0305
Non-resorbable	0.741	0.173	0.402; 1.080	<.0001
ST augmentation	-0.404	0.113	-0.625; -0.183	.0003
σ^2_{Center}	0.000	0.000		
$\sigma^2_{\text{Patient}}$	0.186	0.053		
$\sigma^2_{\text{Implant}}$	0.276	0.038		

Note: Statistically significant values are given in bold. σ^2 : Variance.

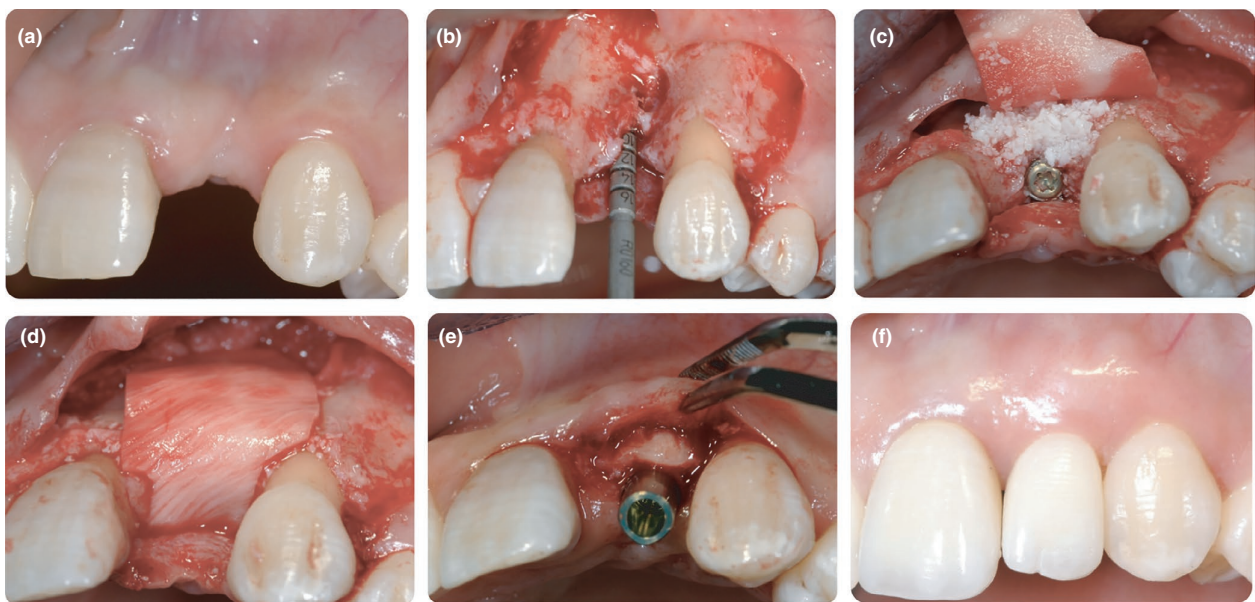


FIGURE 1 (a) Baseline condition of a missing lateral upper incisor (2009); (b) implant placement; (c) application of DBBM in the dehiscence area; (d) a resorbable collagen membrane was adapted; (e) 6 months later, a connective tissue graft was placed at the time of implant uncovering; (f) final crown placement

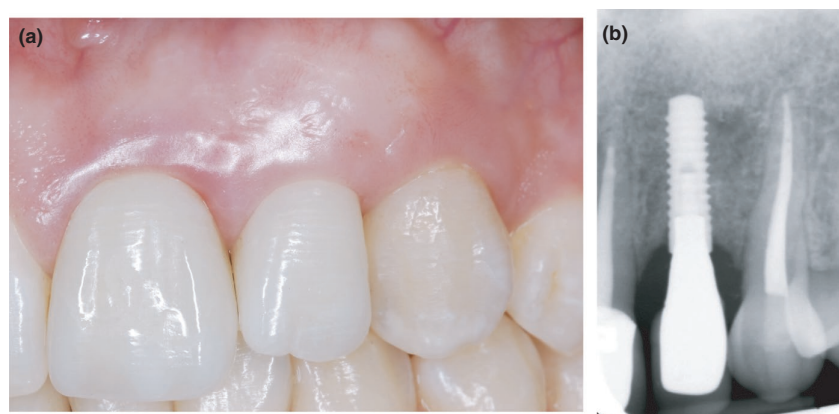


FIGURE 2 (a) Follow-up after 10 years of supportive periodontal therapy; (b) final X-ray evaluation

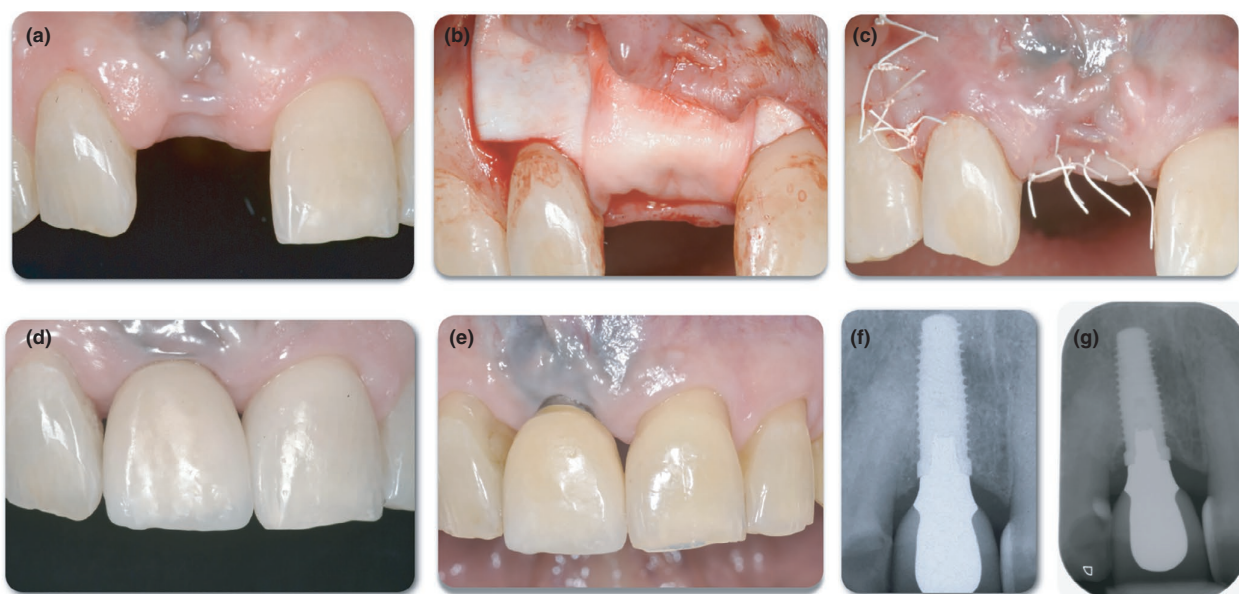
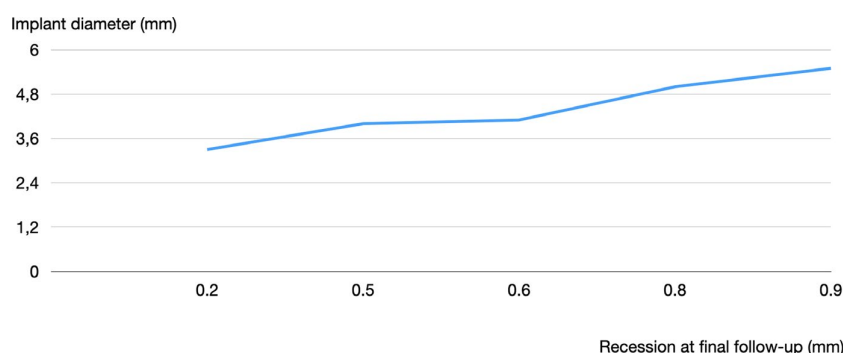


FIGURE 3 (a) Baseline condition of a missing lateral upper incisor (2009); (b) resorbable collagen membrane adapted over the implant and DBBM; (c) the flap; (d) final crown placement; (e) soft tissue condition 9 years later; (f) rx examination at baseline; (g) rx examination at final follow-up

FIGURE 4 Descriptive graph illustrating the association between implant diameter and the mean final mucosal recession at the last follow-up



ACKNOWLEDGEMENTS

This study was partially supported by unrestricted grant by Geistlich Pharma AG.

CONFLICT OF INTEREST

The authors have stated explicitly that there are no conflicts of interest to disclose in connection with this article.

AUTHOR CONTRIBUTION

Francesco Cairo: Conceptualization (equal); Data curation (equal); Funding acquisition (equal); Investigation (equal); Methodology (equal); Project administration (equal); Supervision (equal); Writing-original draft (equal); Writing-review & editing (equal). **Raffaele Cavalcanti:** Investigation (equal). **Luca Landi:** Investigation (equal). **Antonio Rupe:** Investigation (equal). **Nicola Marco Sforza:** Investigation (equal). **Riccardo Pace:** Investigation. **Luigi Barbato:** Data curation (equal); Investigation (equal).

ORCID

Francesco Cairo  <https://orcid.org/0000-0003-3781-1715>

REFERENCES

- Balshi, T. J., Wolfinger, G. J., Stein, B. E., & Balshi, S. F. (2015). A long-term retrospective analysis of survival rates of implants in the mandible. *The International Journal of Oral & Maxillofacial Implants*, 30(6), 1348–1354. <https://doi.org/10.11607/jomi.3910>
- Benic, G. I., Bernasconi, M., Jung, R. E., & Hämmerle, C. H. (2017). Clinical and radiographic intra-subject comparison of implants placed with or without guided bone regeneration: 15-year results. *Journal of Clinical Periodontology*, 44(3), 315–325. <https://doi.org/10.1111/jcpe.12665>
- Benic, G. I., Ge, Y., Gallucci, G. O., Jung, R. E., Schneider, D., & Hämmerle, C. H. (2017). Guided bone regeneration and abutment connection augment the buccal soft tissue contour: 3-year results of a prospective comparative clinical study. *Clinical Oral Implants Research*, 28(2), 219–225. <https://doi.org/10.1111/clr.12786>
- Benic, G. I., & Hämmerle, C. H. F. (2014). Horizontal bone augmentation by means of guided bone regeneration. *Periodontology 2000*, 66, 13–40. <https://doi.org/10.1111/prd.12039>

- Berglundh, T., Armitage, G., Araujo, M. G., Avila-Ortiz, G., Blanco, J., Camargo, P. M., ... Zitzmann, N. J. (2018). Peri-implant diseases and conditions: Consensus report of workgroup 4 of the 2017 World Workshop on the Classification of Periodontal and Peri-Implant Diseases and Conditions. *Journal of Clinical Periodontology*, 45(Suppl. 20), S286–S291. <https://doi.org/10.1111/jcpe.12957>
- Boardman, N., Darby, I., & Chen, S. (2016). A retrospective evaluation of aesthetic outcomes for single-tooth implants in the anterior maxilla. *Clinical Oral Implants Research*, 27(4), 443–451. <https://doi.org/10.1111/clr.12593>
- Bonde, M. J., Stokholm, R., Schou, S., & Isidor, F. (2013). Patient satisfaction and aesthetic outcome of implant-supported single-tooth replacements performed by dental students: A retrospective evaluation 8 to 12 years after treatment. *European Journal of Oral Implantology*, 6(4), 387–395.
- Cairo, F., Barbato, L., Selvaggi, F., Baielli, M. G., Piattelli, A., & Chambrone, L. (2019). Surgical procedures for soft tissue augmentation at implant sites. A systematic review and meta-analysis of randomized controlled trials. *Clinical Implant Dentistry and Related Research*, 21(6), 1262–1270. <https://doi.org/10.1111/cid.12861>
- Cairo, F., Barbato, L., Tonelli, P., Batalocco, G., Pagavino, G., & Nieri, M. (2017). Xenogeneic collagen matrix versus connective tissue graft for buccal soft tissue augmentation at implant site. A randomized, controlled clinical trial. *Journal of Clinical Periodontology*, 44(7), 769–776. <https://doi.org/10.1111/jcpe.12750>
- Cairo, F., Pagliaro, U., & Nieri, M. (2008). Soft tissue management at implant sites. *Journal of Clinical Periodontology*, 35, 163–167. <https://doi.org/10.1111/j.1600-051X.2008.01266.x>
- Chen, S. T., Darby, I. B., & Reynolds, E. C. (2007). A prospective clinical study of non-submerged immediate implants: Clinical outcomes and esthetic results. *Clinical Oral Implants Research*, 18(5):552–562.
- Chiapasco, M., & Zaniboni, M. (2009). Clinical outcomes of GBR procedures to correct peri-implant dehiscences and fenestrations: A systematic review. *Clinical Oral Implants Research*, 20, 113–123. <https://doi.org/10.1111/j.1600-0501.2009.01781.x>
- Ferreira, S. D., Silva, G. L., Cortelli, J. R., Costa, J. E., & Costa, F. O. (2006). Prevalence and risk variables for peri-implant disease in Brazilian subjects. *Journal of Clinical Periodontology*, 33(12), 929–935. <https://doi.org/10.1111/j.1600-051X.2006.01001.x>
- Heitz-Mayfield, L. J., & Salvi, G. E. (2018). Peri-implant mucositis. *Journal of Clinical Periodontology*, 45, S237–S245.
- Hosseini, M., Worsaae, N., & Gotfredsen, K. (2020). Tissue changes at implant sites in the anterior maxilla with and without connective tissue grafting: A five-year prospective study. *Clinical Oral Implants Research*, 31(1), 18–28. <https://doi.org/10.1111/clr.13540>
- Iorio-Siciliano, V., Blasi, A., Sammartino, G., Salvi, G. E., & Sculean, A. (2020). Soft tissue stability related to mucosal recession at dental implants: A systematic review. *Quintessence International*, 51(1), 28–36. <https://doi.org/10.3290/j.qi.a43048>
- Jemt, T. (2018). Implant survival in the edentulous jaw: 30 years of experience. Part II: A retro-prospective multivariate regression analysis related to treated arch and implant surface roughness. *The International Journal of Prosthodontics*, 31(6), 531–539. <https://doi.org/10.11607/ijp.5883>
- Julious, S. A. (2010). *Sample size for clinical trials* (p. 71). Boca Raton, MACRC Pres.
- Jung, R. E., Fenner, N., Hämmerle, C. H., & Zitzmann, N. U. (2013). Long-term outcome of implants placed with guided bone regeneration (GBR) using resorbable and non-resorbable membranes after 12–14 years. *Clinical Oral Implants Research*, 24(10), 1065–1073. <https://doi.org/10.1111/j.1600-0501.2012.02522.x>
- Jung, R. E., Herzog, M., Wolleb, K., Ramel, C. F., Thoma, D. S., & Hämmerle, C. H. (2017). A randomized controlled clinical trial comparing small buccal dehiscence defects around dental implants treated with guided bone regeneration or left for spontaneous healing. *Clinical Oral Implants Research*, 28(3), 348–354. <https://doi.org/10.1111/clr.12806>
- Lutz, R., Neukam, F. W., Simion, M., & Schmitt, C. M. (2015). Long-term outcomes of bone augmentation on soft and hard-tissue stability: A systematic review. *Clinical Oral Implants Research*, 26, 103–122. <https://doi.org/10.1111/clr.12635>
- Merli, M., Merli, I., Raffaelli, E., Pagliaro, U., Natri, L., & Nieri, M. (2016). Bone augmentation at implant dehiscences and fenestrations. A systematic review of randomised controlled trials. *European Journal of Oral Implantology*, 9(1), 11–32.
- Naenni, N., Lim, H. C., Papageorgiou, S. N., & Hämmerle, C. H. F. (2019). Efficacy of lateral bone augmentation prior to implant placement: A systematic review and meta-analysis. *Journal of Clinical Periodontology*, 46, 287–306. <https://doi.org/10.1111/jcpe.13052>
- Pjetursson, B. E., Helbling, C., Weber, H. P., Matuliene, G., Salvi, G. E., Brägger, U., ... Lang, N. P. (2012). Peri-implantitis susceptibility as it relates to periodontal therapy and supportive care. *Clinical Oral Implants Research*, 23(7), 888–894. <https://doi.org/10.1111/j.1600-0501.2012.02474.x>
- Romanos, G. E., Delgado-Ruiz, R., & Sculean, A. (2019). Concepts for prevention of complications in implant therapy. *Periodontology 2000*, 81(1), 7–17. <https://doi.org/10.1111/prd.12278>
- Sanz-Sánchez, I., Carrillo de Albornoz, A., Figuero, E., Schwarz, F., Jung, R., Sanz, M., & Thoma, D. (2018). Effects of lateral bone augmentation procedures on peri-implant health or disease: A systematic review and meta-analysis. *Clinical Oral Implants Research*, 29, 18–31. <https://doi.org/10.1111/clr.13126>
- Schwarz, F., Sahm, N., & Becker, J. (2012). Impact of the outcome of guided bone regeneration in dehiscence-type defects on the long-term stability of peri-implant health: Clinical observations at 4 years. *Clinical Oral Implants Research*, 23(2), 191–196. <https://doi.org/10.1111/j.1600-0501.2011.02214.x>
- Small, P. N., & Tarnow, D. P. (2000). Gingival recession around implants: A 1-year longitudinal prospective study. *The International Journal of Oral & Maxillofacial Implants*, 15(4), 527–532.
- Thoma, D. S., Bienz, S. P., Figuero, E., Jung, R. E., & Sanz-Martín, I. (2019). Efficacy of lateral bone augmentation performed simultaneously with dental implant placement: A systematic review and meta-analysis. *Journal of Clinical Periodontology*, 46, 257–276. <https://doi.org/10.1111/jcpe.13050>
- Vandenbroucke, J. P., von Elm, E., Altman, D. G., Gøtzsche, P. C., Mulrow, C. D., Pocock, S. J., ... Egger, M. (2007). Strengthening the reporting of observational studies in epidemiology (STROBE): Explanation and elaboration. *Annals of Internal Medicine*, 147(8), W163–W194. <https://doi.org/10.7326/0003-4819-147-8-200710160-00010-w1>

SUPPORTING INFORMATION

Additional supporting information may be found online in the Supporting Information section.

How to cite this article: Cairo F, Nieri M, Cavalcanti R, et al. Marginal soft tissue recession after lateral guided bone regeneration at implant site: A long-term study with at least 5 years of loading. *Clin Oral Impl Res*. 2020;00:1–9. <https://doi.org/10.1111/clr.13658>