

## Advanced Simplified Osteotome Technique (ASOT): a new technique for sinus augmentation and simultaneous implant placement in patient with extreme bone atrophy

Nicola Marco Sforza <sup>1\*</sup>, Anna Franchini <sup>1</sup>, Romina Gandolfi <sup>1</sup>, Matteo Marzadori <sup>2</sup>

Positioning implants in the rear area of the upper jaw can often present difficulties due to low bone quantity. In cases where pneumatization of the maxillary sinus can be observed, be it associated with a reabsorption of the alveolar crest or not, performing a maxillary sinus augmentation can be recommended. In 1994, Summers introduced a “transcrestal” approach to the maxillary sinus, employing manual instruments designed by this Author – Summers osteotomes – that compress the bone tissue of the implant site both laterally and apically. Subsequently, other authors introduced a series of changes in Summers’ original technique, as far as implant surface, surgical protocol and the use of instruments such as video X-ray and sinuscopy are concerned. The common aspect between Summers’ technique and the Authors who modified it, is the recommendation to perform the mini sinus lift in alveolar crests with residual dimensions  $\geq 5$  mm.

Through the description of a clinical case that is part of a longitudinal study yet to be completed, the objective of this clinical study is to present an original technique for sinus elevation with crestal approach and simultaneous insertion of implants, called “Advanced Simplified Osteotome Technique” (ASOT) which improves the predictability of the implant therapy in alveolar crests with sub-sinus vertical dimensions  $\leq 3$  mm.

(J Osteol Biomat 2012; 2:71-81)

**Key words:** Implant, Sinus elevation, Osteotome Technique, Sinus augmentation.

### INTRODUCTION

Positioning implants in the rear area of the upper jaw can often present difficulties due to low bone quantity. The reduction in height and thickness of the alveolar crest can be caused both by an increase in the size of the maxillary sinus (pneumatization), and by bone reabsorption resulting from extractions or outcomes of periodontal diseases. Under these circumstances, in order to correctly position a properly sized implant, a large number of techniques aimed at increasing bone quantity have been described: maxillary sinus floor augmentation, bone grafts, Guided Bone Regeneration (GBR), or a combination of these. In cases where pneumatization of the maxillary sinus can be observed, be it associated with a reabsorption of the alveolar crest or not, performing a maxillary sinus augmentation with lateral or crestal approach can be recommended.

Maxillary sinus floor augmentation with lateral approach – sometimes known informally as “sinus lift” – is the most frequently applied technique. It was first described by Tatum<sup>1</sup> and it is performed by accessing the sinus via a “window” placed on the lateral wall of the maxillary bone and by inserting graft material apically to the sinus floor. Long-term success of this proce-

<sup>1</sup> Private practice, Bologna, Piazza Aldrovandi 12, Italy

<sup>2</sup> Private practice, Medicina, Bologna, Via Saffi 20, Italy

#### Corresponding author:

\*Sforza, Nicola Marco, DDS, private practice, Bologna, Piazza Aldrovandi 12.

tel: 051 222542, 051 7459053 - fax: 051 6568042 - mail: nsforza@studiosforza.net.

ture, along with its technical, implant and prosthetic aspects, are well documented in scientific literature<sup>2</sup>.

In 1994, Summers introduced a less invasive approach to sinus floor augmentation, i.e. Osteotome Sinus Floor Elevation (OSFE) e Bone Added Osteotome Sinus Floor Elevation (BAOSFE). These techniques use a “transcrestal” approach to the maxillary sinus, employing manual instruments designed by the Author – Summers osteotomes – that compress the bone tissue of the implant site both laterally and apically. The first study was carried out on a population of 55 patients who presented alveolar crests with a residual height ranging from 5 to 10 mm. With 143 implants inserted, success rate equaled 96%<sup>3-4-5-6</sup>.

Subsequently, other authors introduced a series of changes in Summers’ original technique, as far as implant surface, surgical protocol and the use of instruments such as video X-ray and sinuscopy are concerned.

In particular, Bruschi et al. (1998), in a longitudinal study carried out on 303 patients and 499 implants, propounded the use of instruments different from Summers’ osteotomes for preparing the implant site, achieving a success rate of 97.5%, according to Albrektsson’s criteria<sup>7</sup>. Deporter et al. (2000) placed emphasis on the use of porous surfaces when placing implants in crests having a residual vertical dimension lower than 5 mm. 26 implants placed on 16 patients were 100% successful<sup>8</sup>; Cavicchia et al. (2001) conducted a study on 97 implants, obtaining a success rate of 88.6%, and they suggested that the fracture of the sinus

floor be performed without interposing graft material between osteotome and bone cortex<sup>9</sup>.

The common aspect between Summers’ technique and the Authors who modified it, is the recommendation to perform the mini sinus lift in alveolar crests with residual dimensions  $\geq 5$  mm.

In support of this thesis, Rosen et al. (1999) conducted a retrospective, multicenter study to assess the effectiveness of Summers’ procedure on 101 patients and 174 implants. Survival rate was 96% in alveolar crests with residual height  $\geq 5$  mm and 85.7% in crests with residual height  $< 5$ mm<sup>10</sup>.

In 2008, in a longitudinal study on 26 patients and 39 implants, Sforza et al. modified Summers’ technique with a combined use of burs and osteotomes that reduces further the morbidity of the mini sinus lift technique with the crestal approach. This procedure, known as Simplified Osteotome Technique (SOT), allows to obtain high implant success rates (97%) on crests with residual height  $\geq 5$  mm<sup>11</sup>.

These results have also been confirmed by Pjetursson et al. in a longitudinal study on 181 patients and 252 implants. In particular, survival rate was 91.3% in residual alveolar crests  $\leq 4$  mm, 90% in

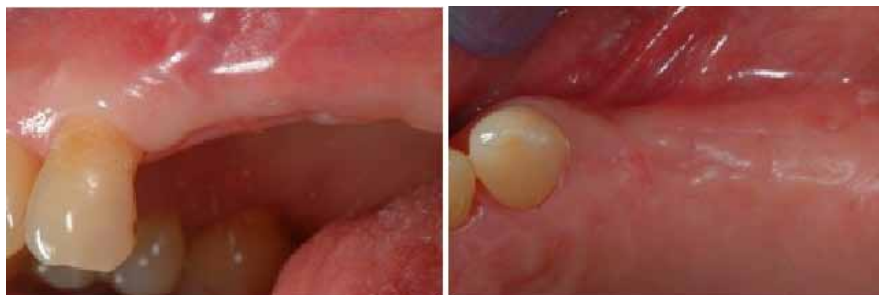residual alveolar crests ranging from 4 mm to 5 mm and 100% in residual alveolar crests  $> 5$  mm<sup>12</sup>.

These data show that the height of the residual crest is a crucial factor for the effectiveness of sinus elevation techniques with transcrestal approach, in that it influences its success rates.

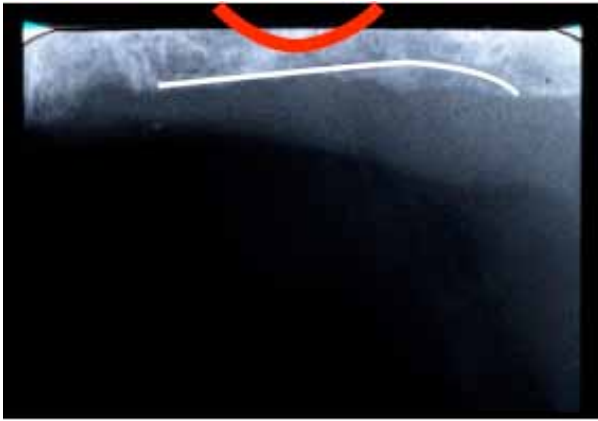Through the description of a clinical case that is part of a longitudinal study yet to be completed, the objective of this clinical study is to present an original technique for sinus elevation with crestal approach and simultaneous insertion of implants, called “Advanced Simplified Osteotome Technique” (ASOT) which, combined with SOT, allows to improve the predictability of the implant therapy in alveolar crests with subsinus vertical dimensions  $\leq 3$  mm.

#### CASE REPORT

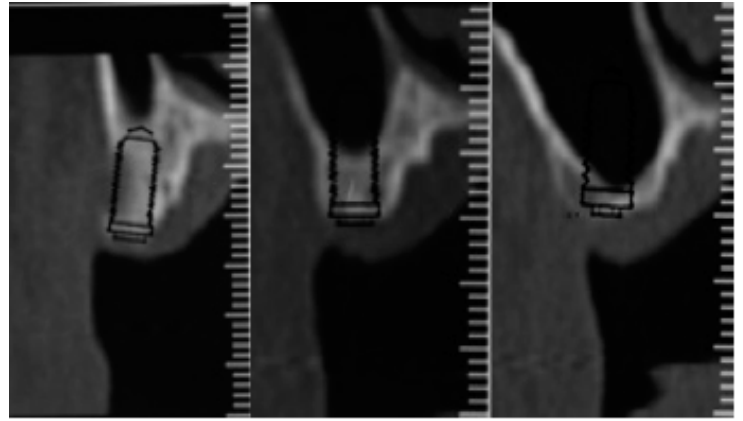
The patient (B.G., 67 years old, male) was sent to us by a colleague, to restore the upper-left sector by means of an implant prosthetic therapy. Overall, the patient was in good health, with no chronic systemic diseases, non-smoker. Five months prior to the dental examination, teeth number 24 and 27 were extracted. From a clinical point of view, there were no signs of active periodon-



**Figures 1a, 1b.** Clinical pictures of the edentulous crest, where a massive vertical and horizontal bone resorption can be seen clearly.



**Figures 2a.** Intraoral X-ray of quadrant II: the residual sub-sinus bone volume available for implant positioning is low.



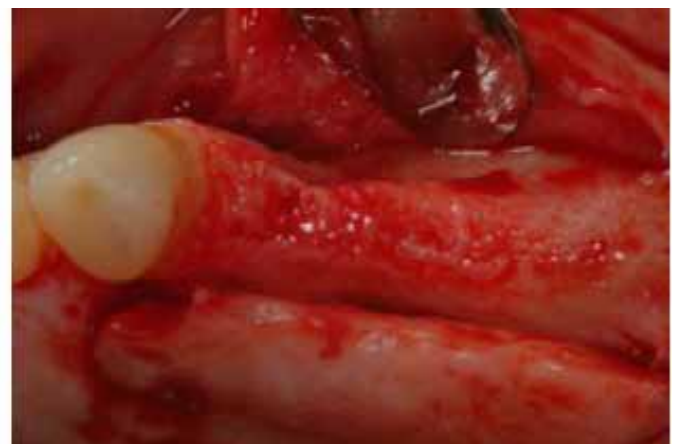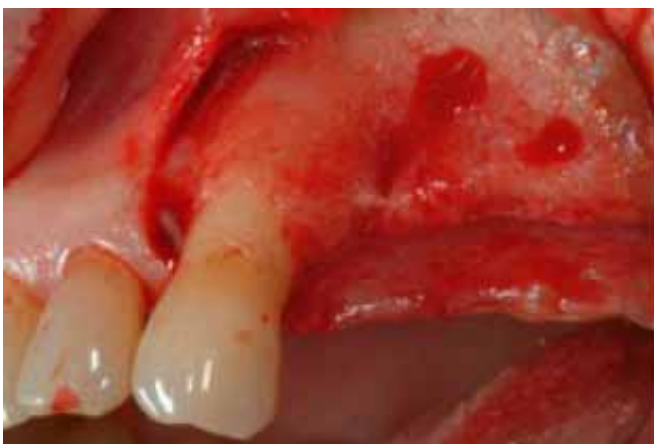**Figures 2b.** CT scan image showing a superimposition of the implant templates in position 24, 25 and 26. Bone quantity needs to be increased.

titis. Good level of oral hygiene, with Full Mouth Plaque Score (FMPS) and Full Mouth Bleeding Score (FMBS) < 15%. A maintenance therapy program with periodic sessions was scheduled. In quadrant II, a vertical and horizontal vestibular atrophy of the bone crest (Figures 1a, b). The patient had undergone a CT scan 2 months prior to the examination, in which a reduced quantity of sub-sinus residual bone (up to <3mm) could be observed. It had probably been caused by the reabsorption of the edentulous crest and by the pneumatization of the maxillary sinus. This was also confirmed by an intraoral

X-ray examination of quadrant II (Picture 2a). A template of the implant was applied onto the CT scan images in order to measure the quantity of residual bone: 9 mm in area 24; 5 mm in area 25 and 2 mm in area 26 (Picture 2b). Bone quality was assessed subjectively by the surgeon expert in implant therapy, upon surgery, while using the first surgical bur. Based on the clinical and radiographic observation and on the analysis of the case studies, the surgeon scheduled the placement of a 4x10mm implant in position 24 without sinus floor elevation, of a 4x10mm implant in position 25 applying the SOT

technique and of a 5x10mm implant in position 26 with the new ASOT procedure. Moreover, a procedure for increasing the horizontal volume of the vestibular bone crest in areas 24 and 25 was also scheduled.

After signing the informed consent form, the patient was administered a non-steroidal anti-inflammatory drug (Aulin®, 100 mg; Roche, Milan, Italy) and an antibiotic (Amoxicillin EG®, 2 g) and a mild sedative (Valpinax®, 20 mg; Crinos) one hour before surgery. Lidocaine was used for local anesthesia (Ecocaine® 20 mg, Molteni Dental; solution: 1:50000).



**Figures 3a, 3b.** Full-thickness flap elevation with releasing incisions.

A linear, crestal incision was performed, with mesial releasing incisions on tooth 23, both vestibularly and lingually. A flap was elevated full-thickness above the mucogingival line, with complete reposition of the residual bone crest (Figures 3a, b).

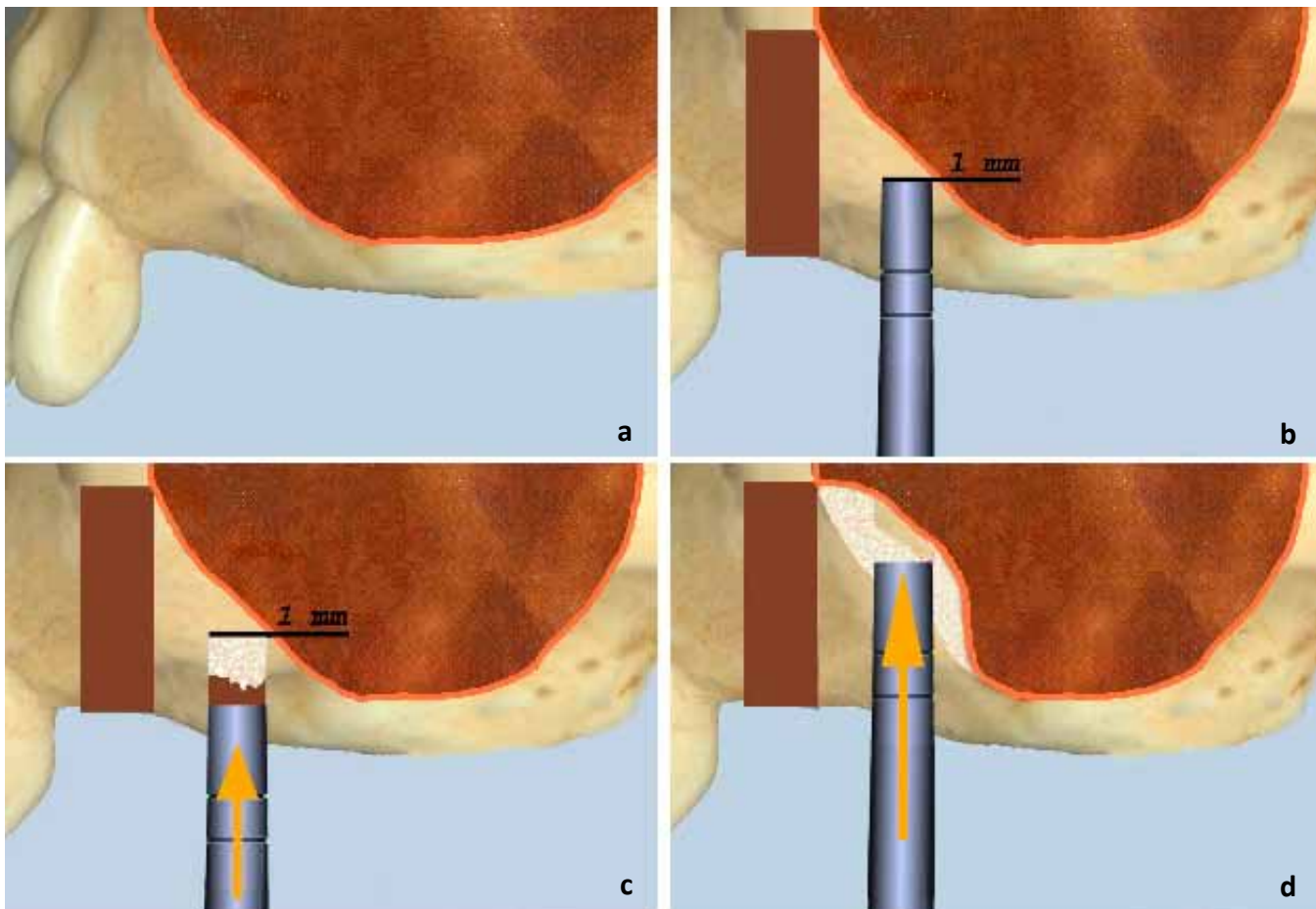
*Preparation of the implant sites and implant positioning:*

- Residual bone quantity: 9 mm. Bone quality: type II/III<sup>13</sup>. The site was prepared using traditional dental burs: ball diameter 2, twist drill diameter 2, pilot

drill diameter 2/3, twist drill diameter 2.8; the site so prepared was not countersunk nor tapped.

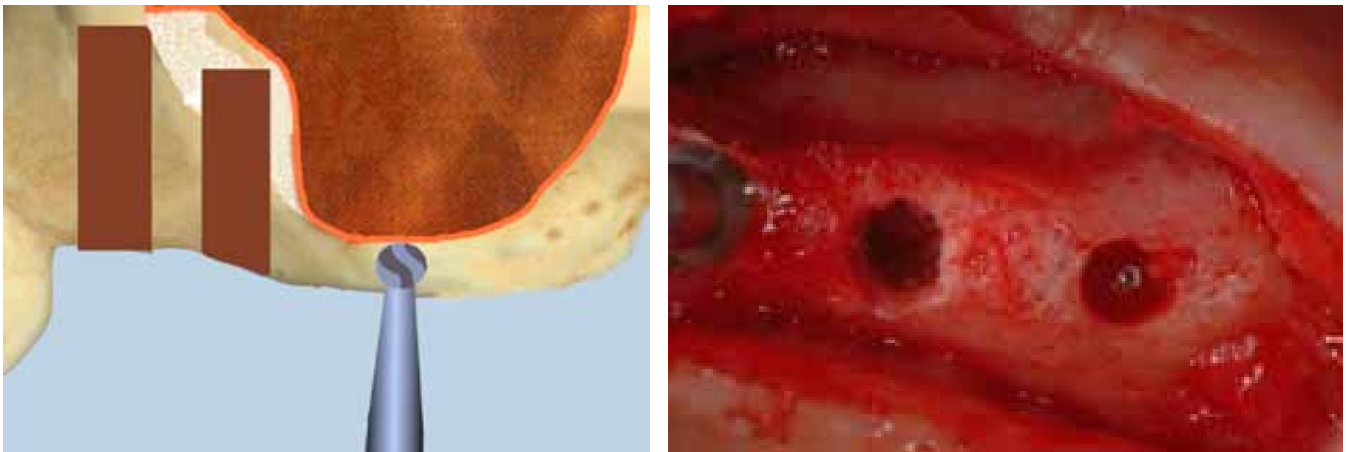
- Residual bone quantity: 5 mm. Bone quality: type IV<sup>13</sup>. The site was prepared using the SOT technique as described in literature<sup>11</sup>; the following stages were followed: *a guide hole was drilled with a ball drill with diameter = 2 mm; preparation of the implant site using only Summers' osteotomes with increasingly larger diameters numbers 1, 2 and 3, which were rotated and pressed manually to reach the working*

*depth; preparation of the graft material, composed of bovine demineralized bone (BIO-OSS®); fracture of the sinus floor after having inserted and compacted a small amount of grafting material, by using the last osteotome used to prepare the implant site, on which the pressure of 2-3 light strokes of a surgical hammer was applied; sinus lift with subsequent increases of the grafting material and compaction using the osteotomes, which were inserted manually for 5 mm except for the last compaction procedure, which was*



**Figures 4a, b, c, d.** Site 25: performance of SOT technique.

**Figure 4a.** Graphic illustration of the pre-implant site. **Figure 4b.** preparation of site 25 with manual instruments having increasing diameter no.1, 2 and 3 at 1 mm from sinus floor. **Figure 4c.** Positioning of graft material and sinus floor fracture by means of the last osteotome used for implant site preparation. **Figure 4d.** Sinus floor elevation by adding small amounts of graft materials and implant site preparation with manual instruments at a working length of 9 mm (1 mm less than the length of the implant to be positioned).



**Figures 5a, b.** ASOT technique.

**Figures 5a.** A guide hole was performed in position 26 by means of a ball drill with diameter = 2 mm. **Figures 5b.** Occlusal clinical photograph of site 26 after having performed and expanded the guide hole: the Schneiderian membrane is intact.

performed at a depth of 9 mm (1 mm less than the original implant length). At each stage, after the fracture of the sinus floor, the Valsalva maneuver was performed in order to verify, from a clinical point of view, that the Schneiderian membrane was not perforated (Figures 4a, b, c, d).

- Residual vertical bone quantity: 2 mm. Bone quality: type IV<sup>13</sup>. The site was prepared using the new, modified SOT technique (ASOT) to approach residual bone crests with dimensions  $\leq 3$  mm:

- I. A guide hole was drilled with a ball drill with diameter = 2 mm to a depth of 1 mm from the sinus floor;
- II. Preparation of the implant site: the site was prepared using the same ball drill until the Schneiderian membrane was reached. The diameter was enlarged to 3 mm in order to allow access to the manual instruments (Figures 5a, b).
- III. Sinus membrane detachment: by means of an alveolar curette Lucas HFCL 84-E5, the membrane was detached for about 1 mm, in a circumferential direction in relation to

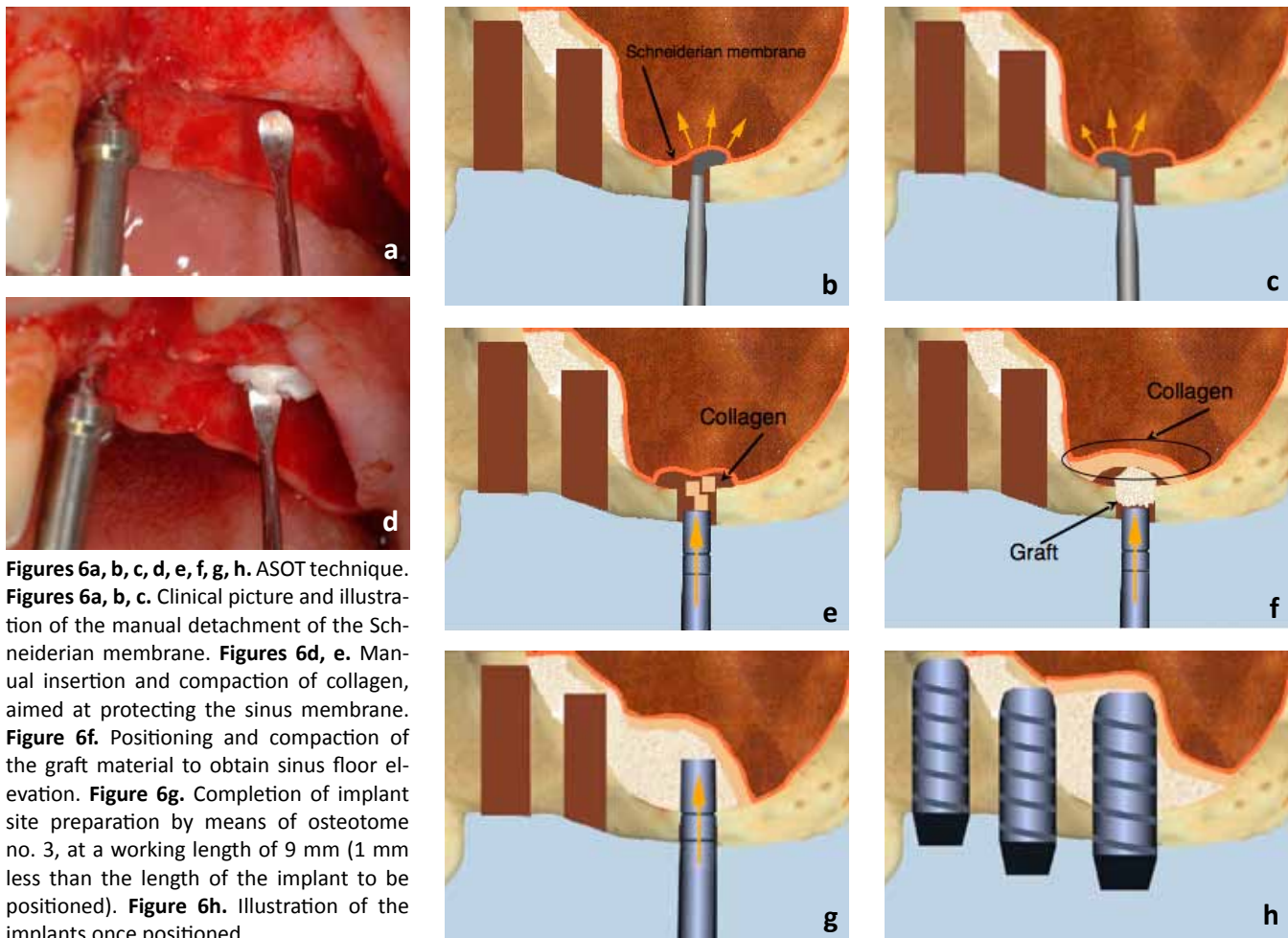
the access hole. This procedure was possible thanks to the low resistance of the membrane as a result of the sinus lift already performed on the mesial site with the SOT technique. Subsequently, collagen – accurately dimensioned, i.e. cut in small cubes with sides measuring 3 mm – was positioned and by means of the osteotomes, which were never pushed beyond the sinus floor, it was compacted toward the membrane in 5-6 times subsequently.

- IV. Sinus lift: small amounts of grafting material (demineralized bovine bone – BioSS®) were added 4-5 times subsequently and carefully compacted with osteotome no. 3, to reach a maximum depth of 5 mm. At the end of this procedure, the osteotome was pushed delicately to a depth of 9 mm (1 mm less than the original implant length) and the negativity of Valsalva's sign was verified.
- V. Implant positioning: starting from the most mesial position, following a conventional procedure and without using any cooling fluid, the

cylindrical 4X10 implants 3i Biomet Nanotite were inserted in position 24 and 25, and the cylindrical 5X10 implant Nobelbiocare Tiunit MKIV was inserted in position 26, by means of a low-speed handpiece. At the end of the procedure, the following torque values were recorded: 50N for tooth 24, 50N for tooth 25 and 35N for tooth 26 (Figure 6a, b, c, d, e, f, g, h).

It is important to notice that after these procedures the use of osteotomes has created not only a vertical augmentation of the bone quantity but an increase of the bucco-palatal dimension of the alveolar crest as well; that could be observed also from a clinical point of view. (see Figure 3b, 5b).

As there was a minor vestibular dehiscence on tooth 24 and bone thickness measured  $< 2$  mm in the site of tooth 25, the thickness of the peri-implant tissue was increased by adding demineralized bovine bone (BioSS®) covered by a connective tissue graft taken from the thickest palatine flap (Figure 7a, b, c, d).



**Figures 6a, b, c, d, e, f, g, h.** ASOT technique. **Figures 6a, b, c.** Clinical picture and illustration of the manual detachment of the Schneiderian membrane. **Figures 6d, e.** Manual insertion and compaction of collagen, aimed at protecting the sinus membrane. **Figure 6f.** Positioning and compaction of the graft material to obtain sinus floor elevation. **Figure 6g.** Completion of implant site preparation by means of osteotome no. 3, at a working length of 9 mm (1 mm less than the length of the implant to be positioned). **Figure 6h.** Illustration of the implants once positioned.

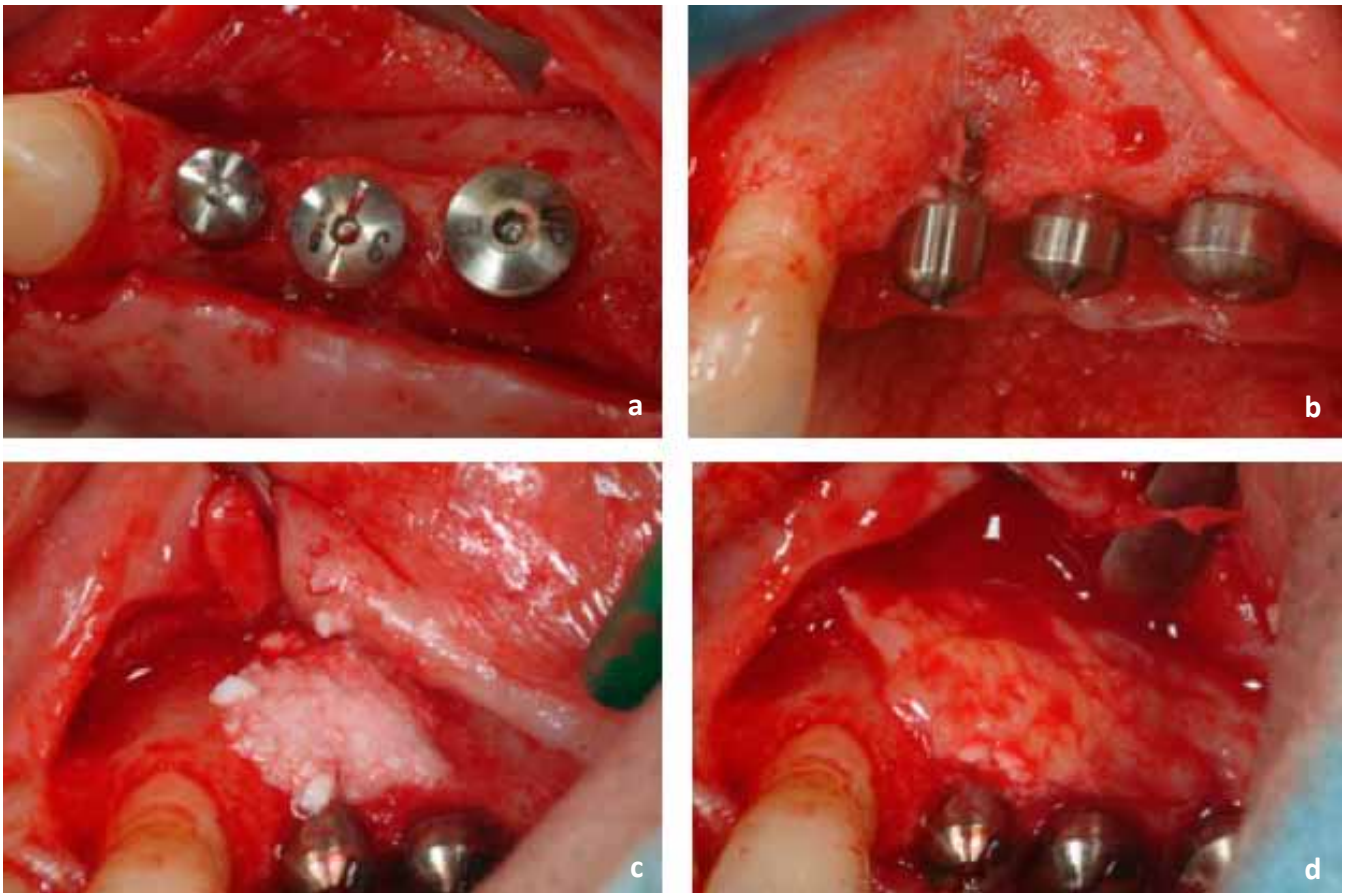
A PTFE monofilament (Gore-Tex®) 5/0 with inverted mattress and interrupted sutures was performed (Figure 8). At the end of the surgery, an intraoral X-ray examination was carried out using the parallel technique in order to check that the sinus floor elevation had been successful (Figure 9). Drug treatment was prescribed with Aulin® (100 mg 12 hours after surgery) and with Amoxicilline EG® (1g/die for 7 days by mouth). Sutures were removed after 10 days. After 6 months, a new intraoral X-ray examination was performed. The implant head impression was taken for

the provision of provisional fixed prostheses to be screwed directly at the implant platform and kept for a three-month period. When the final impression was taken and upon cementation (Figure 10a, b, c, d, e, f), another X-ray examination was taken, which confirmed that the bone levels obtained had been maintained. The patient was included in a customized maintenance therapy protocol with examinations to be held every 3 months and intraoral X-ray examinations at 6 months post cementation, after one year and every following year.

The implants are still in function and meet the Albrektsson's criteria for success after a 3 years loading. (Figure 11a, b).

#### DISCUSSION

Transcrestal maxillary sinus floor elevation allows to place implants with subsequent implant-prosthetic rehabilitation. The procedure is particularly successful in cases in which massive atrophy is present in rear-upper jaws where the dimension of the residual bone crest is reduced due to a pneumatization of the maxillary sinus<sup>2-9,11</sup>. In



**Figures 7a, b, c, d.** Clinical pictures taken immediately after implant positioning. Dehiscence can be noticed in site 24, as well as a reduced residual thickness in site 25, which were offset by adding deproteinized bovine bone (BioOss®) and a connective tissue graft.

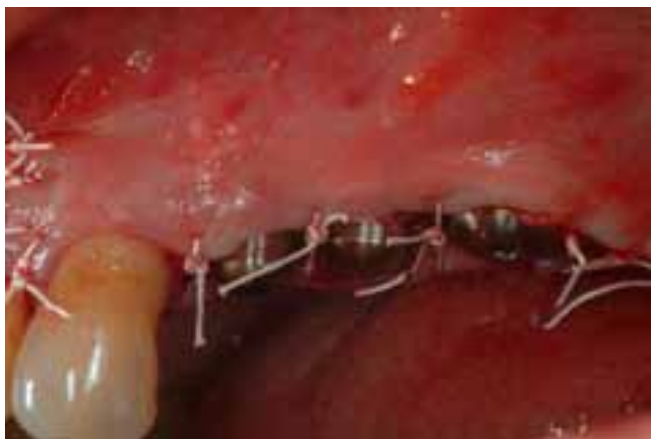particular, scientific literature suggests that the success of the implant placement is strictly related to the vertical dimensions of the residual crest, taking 5 mm as a minimum reference height in order to obtain a high predictability rate<sup>10</sup>.

In clinical reality, situations in which residual bone quantity is equal or lower than 5 mm are rather frequent. For this reason, to develop a mini-elevation technique is particularly interesting, in that it allows to solve complex cases without having to apply more invasive and dangerous methods such as the maxillary sinus floor elevation tech-

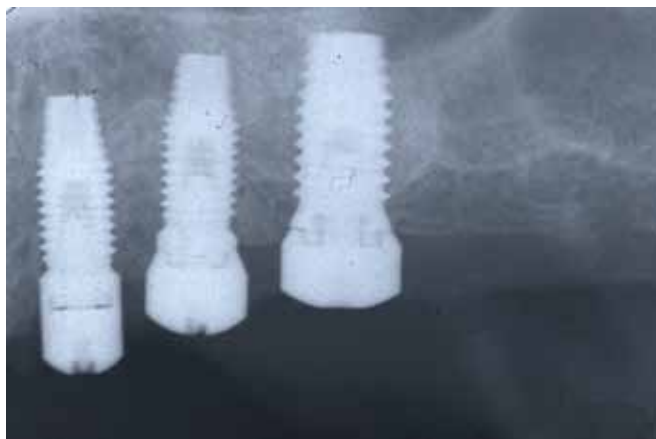nique with lateral approach. Moreover, an important advantage of the transalveolar approach – even in cases in which the dimensions of the bone crest are very low – is that implants are placed simultaneously with the sinus floor elevation, thus ensuring a quick surgical technique with a low morbidity.

In this particular clinical case, 3 implants were placed in position 24, 25 and 26, with a residual vertical bone crest measuring 10 mm, 5 mm and 2 mm, respectively. In all three sites, a high primary stability was achieved. As shown in literature for cases of maxil-

lary sinus floor elevation with lateral approach and simultaneous implant placement when the dimensions sub-sinus residual bone crest are very low<sup>14</sup>, this was possible thanks to the change introduced in the preparation of the implant site. In fact, this determines a sub-preparation of the site itself which, combined with the use of implants having a suitable macro- and micro-structure, allows to achieve high levels of implant stability. Furthermore, in this specific case of maxillary sinus floor elevation with transalveolar approach, the primary stability of the implants was achieved also thanks to a



**Figures 8.** Clinical picture of the PTFE monofilament suture (Gore-Tex®) 5/0 with inverted mattress and interrupted sutures.



**Figures 9.** Post-surgery intraoral X-ray.

lateral and apical bone compaction by means of osteotomes.

The management of Schneiderian membrane is a crucial factor for successful sinus floor elevation and mini-elevation procedures, in that it minimizes post-surgery complications. In a recent systematic review of scientific literature<sup>15</sup>, it was reported that in maxillary sinus floor elevation technique with transcrestal approach, the perforation of the membrane had an incidence ranging from 0% to 21.4%, resulting in post-surgery complications in 2.5% of the cases.

The prognostic meaning of a perforation of the sinus membrane is still unclear; in fact, according to some Authors<sup>16</sup>, the integrity of the membrane does not appear to be crucial to retain the graft material and for the overall success of the technique, whereas according to other Authors<sup>17</sup>, a perforation of the Schneiderian membrane would be the cause of a reduced bone regeneration.

To date, given the absence of reliable scientific evidence, the integrity of the membrane remains a primary objective

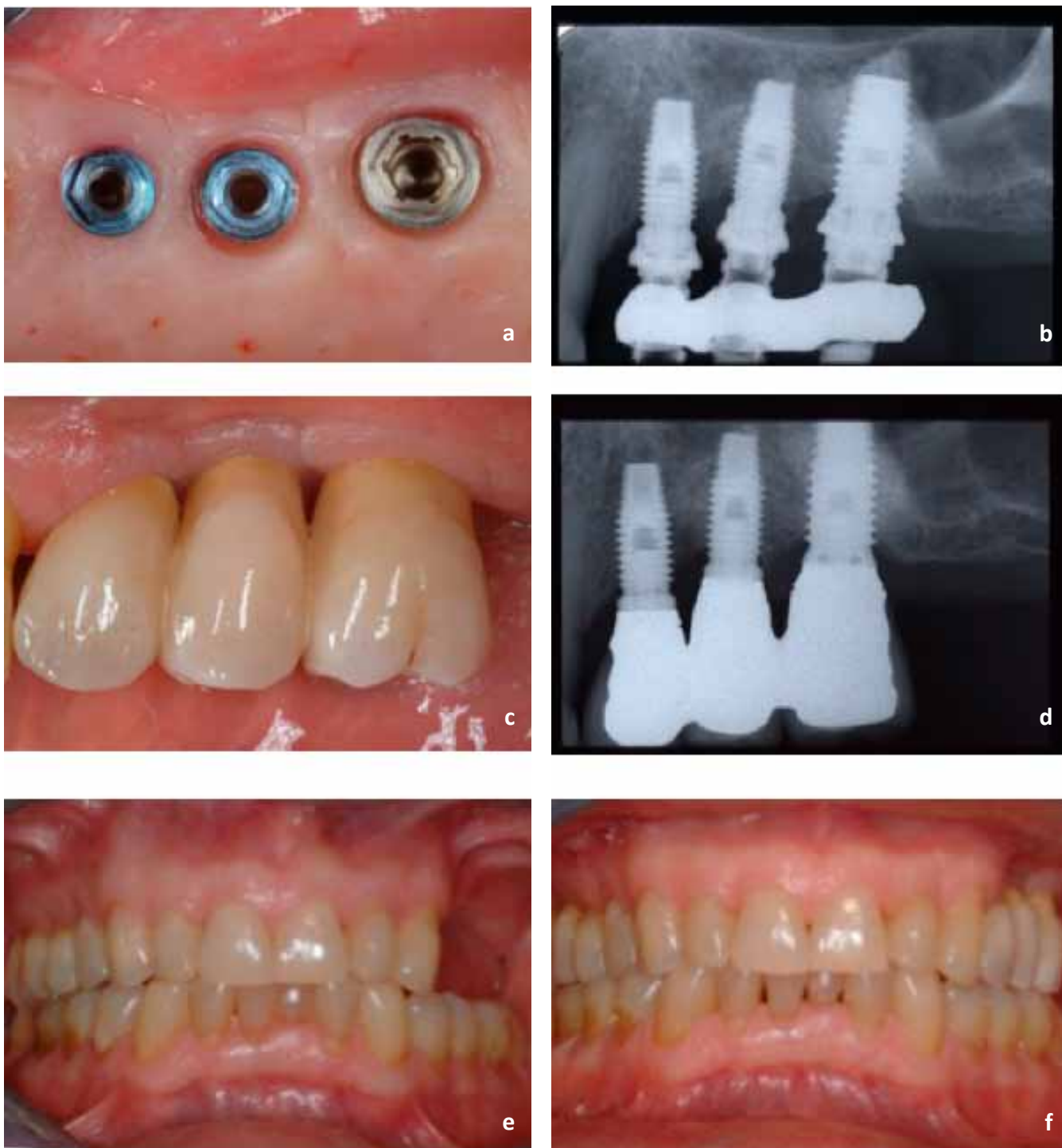
in the procedures for maxillary sinus floor elevation. In the clinical case presented here, a 5 mm sinus elevation in position 25 and a 8 mm sinus elevation in position 26 were obtained. If these elevations had been obtained with a transalveolar approach, the risk of lacerations would have been very high. In order to reduce said lacerations, the Authors suggest the membrane be detached progressively, thus minimizing the strains. In particular, site 25 – with a residual bone quantity of 5 mm – was treated first; the sinus floor elevation was obtained by subsequent additions of biomaterial on the one hand, and by delicately compacting the osteotomes – with increasing diameters – after having used burs, according to the transalveolar technique SOT<sup>11</sup>, on the other. First, the sinus floor elevation in the mesial site was obtained; in site 26, on the other hand, the membrane presented a low strain thanks to its progressive shift toward its mesial component, and an elevation that completed the one already performed in site 25 was obtained, according to the original technique described by the

Authors and referred to as ASOT.

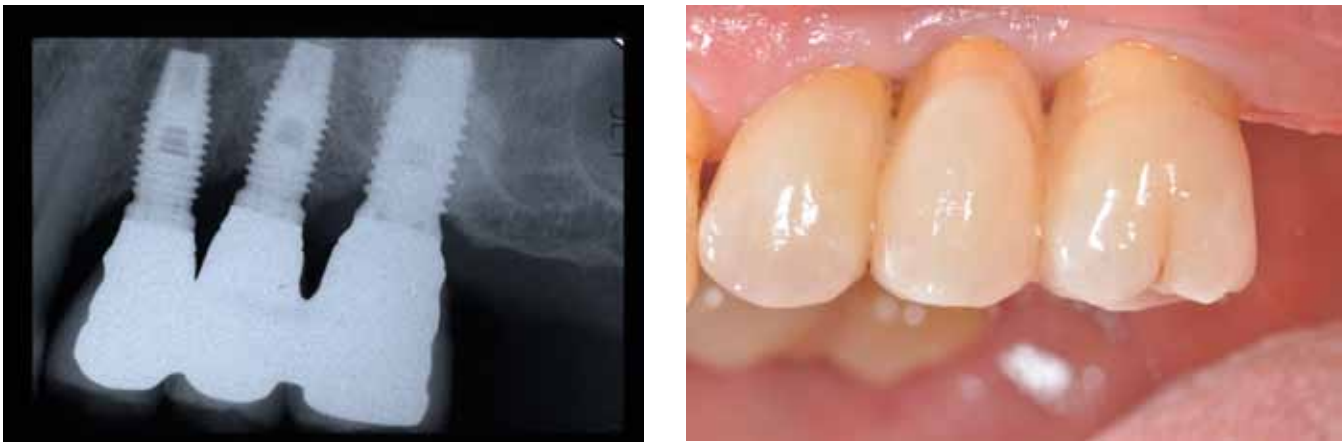
The type of graft material used to obtain the sinus floor elevation determines different biologic responses and healing courses. The use of autologous bone appears to represent the gold standard thanks to the osteoinductive properties that only this type of graft can guarantee<sup>2,13</sup>. However, in order to reduce the morbidity of the surgery and to avoid a second harvesting of graft material, other, highly successful sinus floor elevation techniques have been described in literature, which combine the use of autologous bone with alloplastic material, or even grafts performed with bone surrogate material only. In this regard, in a systematic review of scientific literature<sup>18</sup>, the Authors demonstrated that the implant survival rate after 3 years equaled 88.45% in autologous bone grafts, 90.95% in autologous bone grafts combined with other surrogates, and 95.25% in cases where only bone substitutes were used, such as demineralized bovine bone.

Also from a volumetric point of view, bone surrogate graft materials appear





**Figures 10a, b, c, d.** Clinical pictures and X-ray images taken upon final impression and upon cementation of the final prosthesis.  
**Figures 10e, f.** Comparison between the patient's condition before surgery and after the cementation of the final prosthesis.



**Figures 12a,b.** Clinical pictures and X-ray image taken at the three-years follow-up

to have a higher stability over time<sup>2</sup>. In this regard, the osteoconductive properties of the low-resorption bone surrogate graft material seem to ensure a higher clot stability, as well as to effectively function as a space maintainer. The risk of contraction of the sinus area expanded surgically – which is generally caused by the compression suffered by the membrane at every respiratory act – is therefore lower than in cases where only autologous bone graft or no graft at all are used.

In this study, space is created and maintained thanks to the use of demineralized bovine bone in implant site 25, and to a collagen sponge conveniently fragmented and then combined with demineralized bovine bone in implant site 26, along with the support provided by the simultaneous positioning of the implants. The rationale for the use of the bone substitute was related to the long-term maintenance of a more stable sinus floor elevation volume obtained surgically, as compared to the volume stability that could be obtained by using a collagen sponge only.

### CONCLUSION

The positioning of implants in atrophic rear jaws can also be performed in clinical situations in which the height of the residual bone crest is equal to or lower than 3 mm. In particular, it is crucial to pay special attention to a number of surgical procedures aimed at increase primary stability, such as the sub-preparation of the implant site and the manual condensation by means of osteotomes. The management of the elevation of the Schneiderian membrane must be progressive, i.e. the membrane must be first detached in the area where the bone quantity is higher, then in the areas where atrophy can be observed, in order to minimize the risk of perforation. Therefore, when primary and tissue stability are adequate, the positioning of the implant is made possible thanks to the insertion of graft material and to the compaction with osteotomes.

The ASOT technique offers an alternative approach to the lateral sinus floor elevation technique when massive atrophy of the maxilla is present. How-

ever, more longitudinal studies need to be carried out in order to verify its success rate and the long-term predictability of the results.

## REFERENCES

1. Tatum H. (1986) Maxillary and sinus implant reconstructions. *Dent Clin North Am* 30(2):207-229.
2. Jensen OT, Shulman LB, Block MS, Iacono VJ. Report of the Sinus Consensus Conference of 1996. *Int J Oral Maxillofac Implants* 1998;13 Suppl:11-45. Review.
3. Summers RB. A new concept in maxillary implant surgery: the osteotome technique. *Compend Contin Educ Dent* 1994;15:152-160.
4. Summers RB. The osteotome technique: Part 2 - The ridge expansion technique. *Compend Contin Educ Dent* 1994;15:422-436.
5. Summers RB: The osteotome technique: Part 3 – Less invasive methods of elevating the sinus floor. *Compend Contin Educ Dent* 1994;15:698-708.
6. Summers RB. The osteotome technique: Part 4 – Future site development. *Compend Contin Educ Dent* 1995;16:1090-1099.
7. Bruschi GB, Scipioni A, Calesini G, Bruschi E. Localized management of sinus floor with simultaneous implant placement: a clinical report. *Int J Oral Maxillofac Implants* 1998;13:219-226.
8. Deporter D, Todescan R, Caudry S. Simplifying management of the posterior maxilla using short, porous-surfaced dental implants and simultaneous indirect sinus elevation. *Int J Periodontics Restorative Dent* 2000;20:477-485.
9. Cavicchia F, Bravi F, Petrelli G. Localized augmentation of the maxillary sinus floor through a coronal approach for the placement of implants. *Int J Periodontics Restorative Dent* 2001;21:475-485.
10. Rosen PS, Summers R, Mellado JR et al. The bone-added osteotome sinus elevation technique: multicenter retrospective report of consecutively treated patients. *Int J Oral Maxillofac Implants* 1999;14:853-858.
11. Sforza NM, Marzadori M, Zucchelli G. Simplified osteotome sinus augmentation technique with simultaneous implant placement: a clinical study. *Int J Periodontics Restorative Dent*. 2008;28(3):291-9.
12. Pjetursson BE, Ignjatovic D, Matsu-liene G, Brägger U, Schmidlin K, Lang NP. Transalveolar maxillary sinus floor elevation using osteotomes with or without grafting material. Part II: Radiographic tissue remodeling. *Clin Oral Implants Res*. 2009;20(7):677-83.
13. Lekholm U, Zarb GA. Patient selection and preparation. In Brånemark P-I, Zarb GA, Albrektsson T (eds). Chicago: Quintessence 1985:199-209.
14. Esposito M, Piattelli M, Pistilli R, Pellegrino G, Felice P. Sinus lift with guided bone regeneration or anorganic bovine bone: 1-year post-loading results of a pilot randomised clinical trial. *Eur J Oral Implantol*. 2010;3(4):297-305.
15. Tan WC, Lang NP, Zwahlen M, Pjetursson BE. A systematic review of the success of sinus floor elevation and survival of implants inserted in combination with sinus floor elevation. Part II: transalveolar technique. *J Clin Periodontol*. 2008;35(8 Suppl):241-54.
16. Jensen J, Sindet-Pedersen S, Oliver AJ. Varying treatment strategies for reconstruction of maxillary atrophy with implants: results in 98 patients. *J Oral Maxillofac Surg*. 1994;52(3):210-8.
17. Vlassis JM, Fugazzotto PA. A classification system for sinus membrane perforations during augmentation procedures with options for repair. *J Periodontol*. 1999;70(6):692-9.
18. Del Fabbro M, Rosano G, Taschieri S. Eur J Oral Sci. Implant survival rates after maxillary sinus augmentation. 2008 Dec;116(6):497-506.