


A Less Invasive Approach To Mandibular Horizontal Ridge Augmentation Using Autogenous Bone: A Human Histological Case Series

Diego Capri, DDS¹ • Hyman Smukler, BDS, DMD² • Luca Landi, DDS³

Abstract



Over the years several techniques have been designed to augment atrophic ridges. The approach presented here, using a series of cases for horizontal ridge augmentation, utilizes autogenous bone procured from the recipient site. The employed regenerative procedure, previously

described by the authors, eliminates the need for a distant donor area reducing the potential morbidity. A biodegradable collagen barrier (Ossix) with a slow resorption profile has been successfully employed. Clinical, radiographic and histological results confirm the validity of the selected surgical technique.

KEY WORDS: Dental implants, bone grafting, allograft, autogenous graft, GBR

1. Private Practice, Bologna, Italy

2. Professor Emeritus Department of Periodontology and Oral Biology Boston University H.M. Goldman School of Dental Medicine; Clinical Professor Department of Periodontology University of Pennsylvania School of Dental Medicine; Private practice Brookline MA

3. Private Practice; Roma, Italy

INTRODUCTION

To meet the esthetic needs of today's patients and provide the restorative dentist with prosthetically driven implants, we must be able to recreate an ideal form of the soft and hard tissues that will allow us to deliver a prosthesis harmonious with the adjacent teeth.¹ Several techniques have been described to counteract the physiologic tendency of post-extraction alveolar bone resorption^{2,3} or to augment atrophic ridges.⁴⁻¹² The morbidity of autogenous bone block grafts collected both intra or extra-orally to eliminate edentulous crests deformities is not insignificant.^{13,14} In guided bone regeneration (GBR) procedures the reported rate of membranes exposure remains high.¹⁵ GBR is based on the principles of guided tissue regeneration, where an adequate space for blood clot formation and osteogenesis is provided through the use of a physical barrier that prevents the ingress of competing non-osteogenic soft tissues.¹⁶ Several barriers, both resorbable and non-resorbable, are available on the market and the choice is still somehow controversial.^{5,17} In the event of wound dehiscence, the exposure of a non-resorbable e-PTFE membrane, followed by bacterial contamination, can jeopardize the result of the regenerative procedure.¹⁸ On the other hand the premature exposure of a resorbable membrane usually results in a faster rate of material degradation that negatively affects the regenerative process.^{19,20} The use of a biodegradable barrier with an improved resorption profile, even if exposed to the oral environment, has been successfully reported.^{20,21,22} In order to impede the collapse of the barrier toward the osseous defect, thus reducing the space available for regeneration, several approaches have been designed.^{23,24} The use of autogenous bone chips

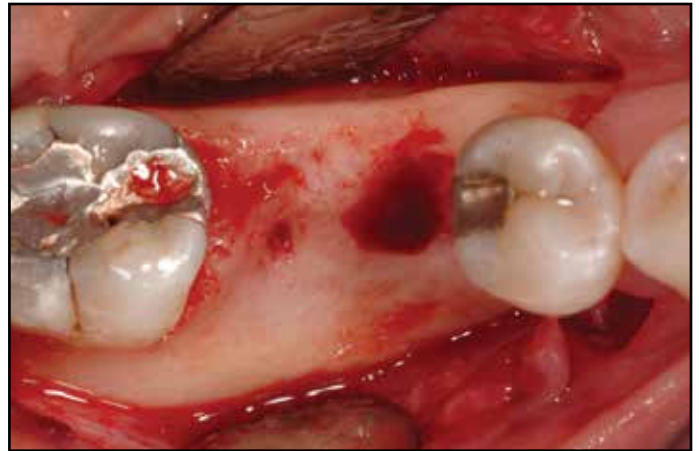


Figure 1: Case I - Preoperative view of the area after reflection of a full thickness flap. Note the buccolingual deficiency.

as graft material, that will also support the membrane, still represents the “gold standard”²³ for alveolar ridge regeneration applying the GBR principles. We have previously reported an innovative approach to horizontal GBR that utilizes autogenous membranous bone obtained in the recipient site, therefore eliminating the need for a donor area with the related potential morbidity.²⁵ The primary objective of the present paper is to further validate, through a series of clinical cases, a newly designed and less invasive surgical technique for mandibular horizontal ridge augmentation. The secondary purpose is to present the histological “proof of principle” that this new procedure does not substantially alter the recipient/donor site where the osteotomy is performed, while newly formed osseous tissue is generated in the area.

TECHNIQUE DESCRIPTION

Upon completion of diagnosis and prognosis (health history, extra and intra-oral examination, radiographic analysis) a detailed explanation of the identified oral pathologies was given to each

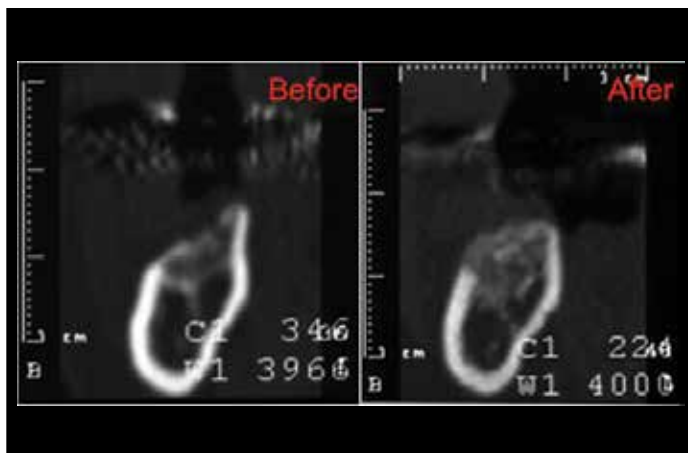


Figure 2: Case I – The composite image shows the CT Scans before and after the regenerative procedure. Note the improved ridge morphology.

patient. As part of the overall treatment plan for all the patients it was suggested to first proceed with a GBR procedure, and subsequently place the implant/s. All the participants signed a specific and detailed informed consent. Under local anesthesia a full thickness flap is elevated both on the buccal and lingual sides of the mandible. After proper mobilization of the flap through periosteal vertical releasing incisions, the autogenous cortico-cancellous graft material is collected in the surgical area either through the trepanation of cores of bone laterally to the atrophic ridge and by harvesting osseous coagulum fragments lingually to the atrophic ridge. More trepanation of the recipient atrophic ridge is usually done with a small round bur. An Allograft material such as Demineralized Bone Matrix (Lifenet, Virginia Beach, Virginia, USA) is utilized to fill the voids left after trephining the cores therefore preventing fall back of the autogenous graft into the donor sites. If needed the DBM can also further augment the volume of the autogenous graft mate-

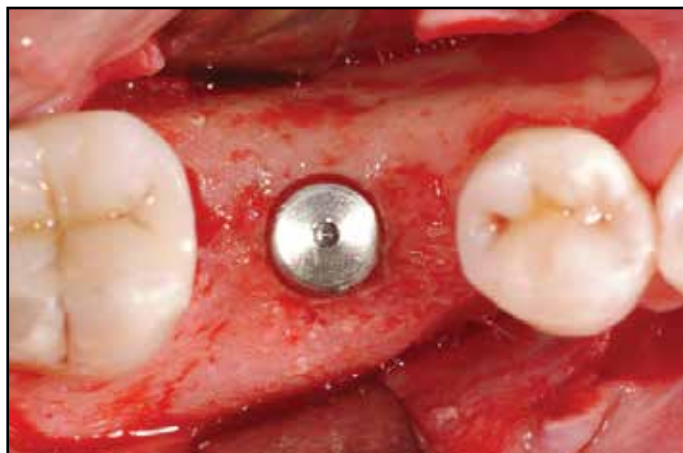

Figure 3: Case I - A 5-mm diameter implant in the proper restorative position could be placed thanks to the improved ridge morphology.

rial. The particulate autogenous bone is gently adapted to the atrophic side of the ridge, and a properly trimmed and rehydrated type I bovine collagen membrane is carefully adapted over the graft (Ossix, Colbar R&D Ltd., Ramat Hasharon, Israel). The barrier is stabilized in place with an initial resorbable horizontal internal mattress suture, or a series of sutures for large defects. Primary closure over the regeneration area is achieved with a mixture of internal mattress and single interrupted sutures. The patient is then dismissed with proper antibiotic, germicidal and analgesic pharmacologic coverage.

HISTOLOGIC ANALYSIS

For each implant site the initial osteotomy was carried out using a 2 mm trephine to harvest a bone core representative of the regenerated site. In three cases, as a control specimen, a core was taken from an untreated area in the proximity of the regenerated site for histological comparison. The bone core was rinsed with sterile saline and immediately immersed into

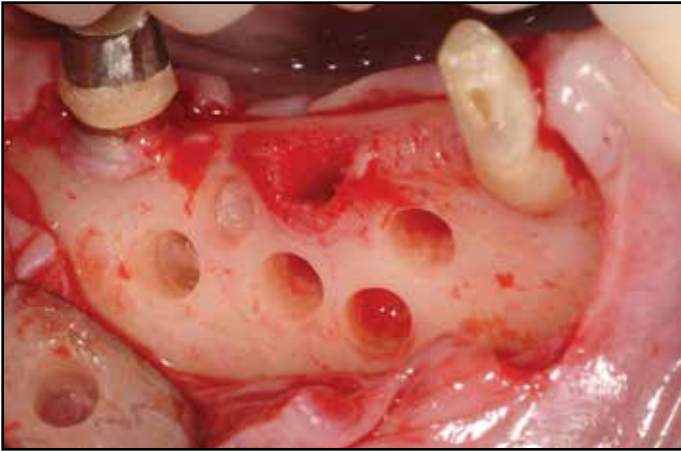


Figure 4: Case II - Full thickness flaps were raised revealing the moderate buccolingual atrophy of the area, a residual socket not fully healed is visible. Multiple cores were obtained.

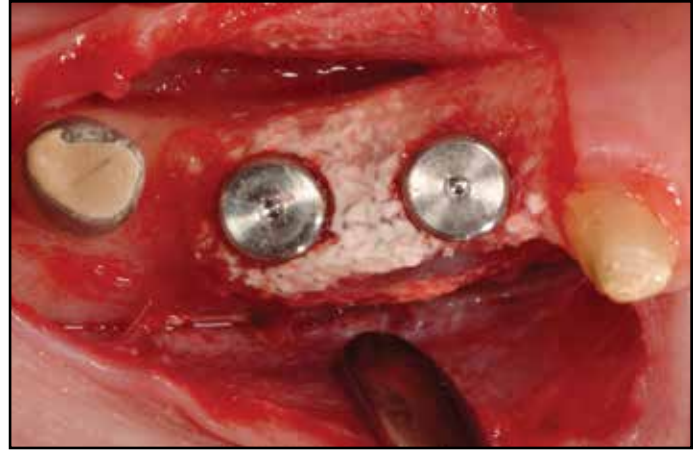


Figure 5: Case II - Two implants were placed in the regenerated area. Note the apparently calcified remnants of the Ossix barrier that could not be removed from the area.

a buffered 10% formalin fixing solution. The specimen was kept refrigerated for approximately 10 days and then sent to the Hard Tissue Laboratory of the Catholic University of Sacred Heart for decalcification and histologic analysis. Briefly, after fixation the biopsies were rinsed thoroughly and decalcified in 20% EDTA buffered to pH 7 for 10 days and then embedded in paraffin. The specimens were then sectioned longitudinally to a thickness of about 6 to 8 μ m and then stained with hematoxylin and eosin and mounted on glass slides for light microscopic evaluation. A minimum of three sections were obtained for each specimen. In some specimens a Gomori staining was utilized.

CASE 1

The patient was a 46-year old female in good general health with no known drug allergies. She reported to be a smoker and it was her desire to regain a healthy mouth. The first

right mandibular molar was extracted 6 months before, due to root fracture, and was to be replaced with a single implant supported restoration. CBCT scan evaluation of the edentulous area revealed a deficient bucco-lingual ridge (Figure 1). The regenerative procedure was accomplished as previously described²⁵ and healing was uneventful. A second CBCT scan of the area was obtained 6 months later (Figure 2) and revealed a significantly improved crestal morphology, which allowed for the ideal placement of a 5 mm diameter implant (Biomet 3i, Palm Beach Gardens, Florida, USA) (Figure 3). Healing was uneventful and, after uncovering, the final restoration was delivered. A histomorphometric analysis was done on the test and control specimens. For the regenerated site the Trabecular bone volume (TBV) was 42.5%, the marrow space occupied 56% of the area while a small percentage of graft material 1.5 % was measured. In the control

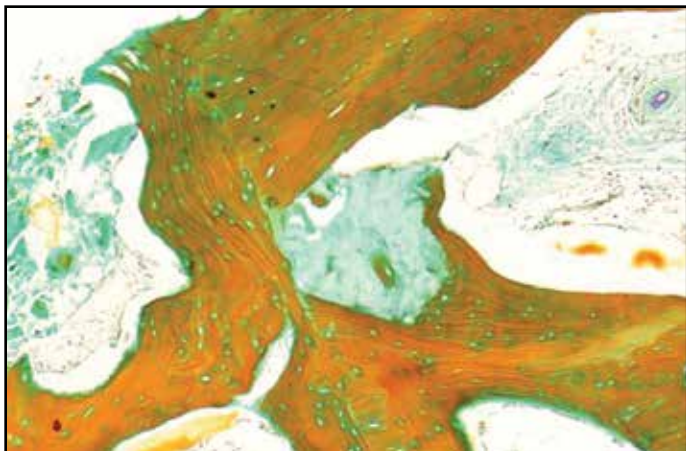


Figure 6: Case II - Histology of the regenerated area - Gomori staining. A DBM particle (center of the picture in blue) is well encased in newly formed woven bone, a blood vessel is centered in his marrow space (top of the picture to the right).

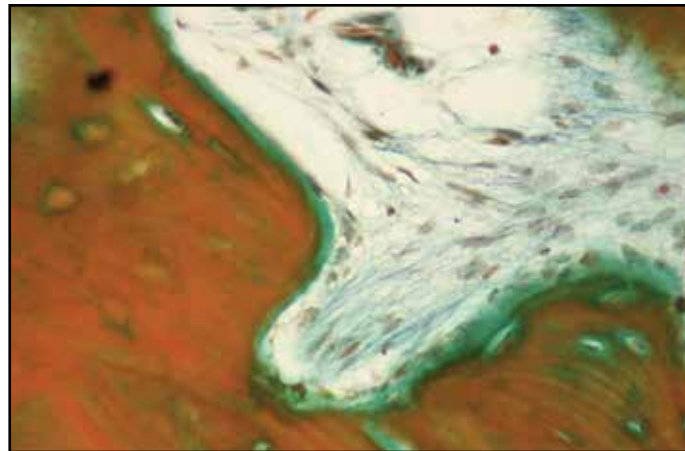


Figure 7: Case II - Histology of the regenerated area, endosteal space at high magnification - Gomori staining. Cellular activity with osseous matrix apposition can be seen (lower right corner of the picture).

core the trabecular bone volume was 58.7% with a percentage of 41.3 of marrow space.

CASE 2

The patient was a 59-year old female with high blood pressure pharmacologically controlled, and with no known drug allergies. She did not smoke and she was referred to receive implants in positions 29 and 30. A CBCT scan revealed a moderate bucco-lingual atrophy of the area. The regenerative procedure was then carried out according to the protocol (Figure 4). No complications occurred following surgery. After five months the patient was sent for a new CBCT scan that revealed an improved condition for implant placement. During implant surgery, some remnants of the previously implanted Ossix membrane were removed, however a significant part of the barrier appeared somehow calcified onto the regenerated area and two 4 mm diameter implants (Biomet 3i, Palm

Beach Gardens, Florida, USA) were placed (Figure 5). Uncovering was performed after four and an half months of uneventful submerged and the case was later restored.

The histologies in the regenerated areas were similar in showing a highly cancellous bone. DBM particles enclosed by normal lamellar osseous tissue were visible in the apical portion of the cores. At higher magnification a DBM particle was encased by newly formed woven bone while a vessel could be seen centered in his marrow space (Figure 6). Signs of cellular activity with osseous matrix apposition can be seen at high magnification on endosteal spaces (Figure 7). The control area displayed a dense lamellar bone with secondary and tertiary osteons and normal remodeling activity. The measured TBV for the regenerated cores was of 54.1% while marrow space account for 38.2% and a 7.7% of graft material was also detectable. In the control area the

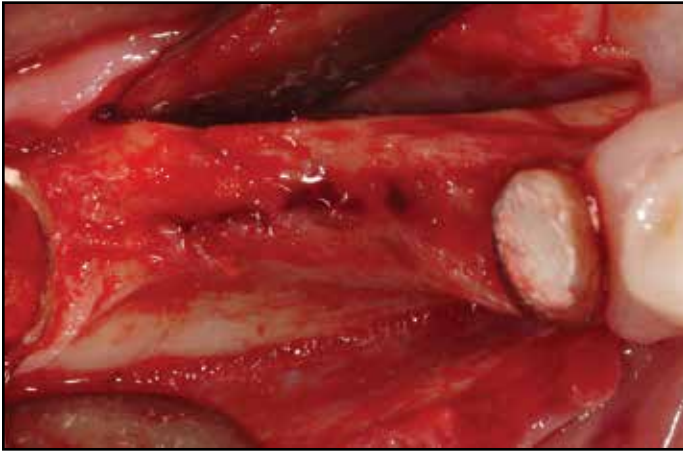


Figure 8: Case III - Full thickness flap was elevated revealing some atrophy of the edentulous ridge.

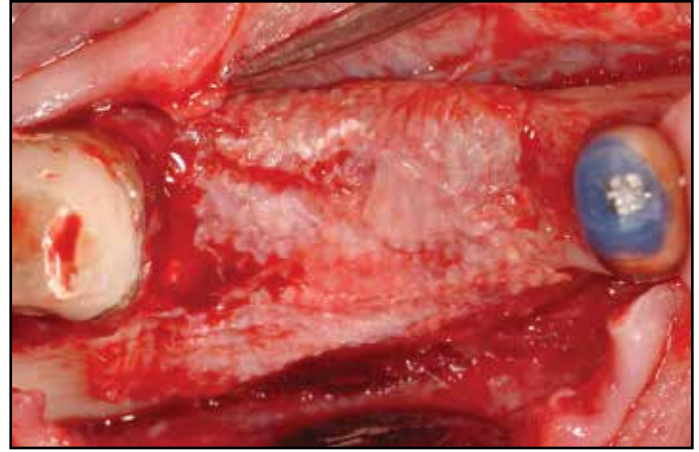


Figure 9: Case III - Nine months after the regenerative procedure remnants of the Ossix membranes could still be seen. The amount of regenerated tissue can be seen comparing with Fig 8.

trabecular bone volume was equal to 62.4% with a volume of marrow space of 37.6%.

CASE 3

A 55-year old female smoker in good general health with no allergies came to our office for comprehensive dental treatment. She presented with old ill-fitting fixed partial dentures. In the fourth quadrant the distal end abutment could not be saved, due to severe periodontitis, and it was decided to temporarily retain it to maintain a provisional prosthesis in the area while implant treatment was completed. Two implants were thus planned for positions 30 and 31. The patient was sent for CBCT scan and the ridge was found to be moderately deficient in the bucco-lingual dimension (Figure 8). The GBR procedure was accomplished without complications and healing was uneventful. After maturation of the graft a second CBCT scan confirmed an improved situation for implant placement. Two 4 mm diameter

implants (Biomet 3i, Palm Beach Gardens, Florida, USA) were placed without complications 9 months following the regenerative procedure. implant surgery remnants of the Ossix membrane could still be identified and removed (Figure 9). After 3.5 months of uncomplicated healing a second stage surgery was performed and the case was later finalized (Figure 10).

The histology of the regenerated ridge revealed some DBM particles surrounded by newly formed lamellar osseous tissue (Figure 11). The bone in the area was rich in marrow spaces with dispersed signs of new bone formation on the endosteal side. No signs of inflammation could be detected. The control sample revealed normally arranged compact lamellar bone. The histomorphometric analysis revealed a mean trabecular bone volume of 50.8% with a 40.9% of mean marrow space and a 8.3% of DBM. The control core presented a 72.4% of trabecular bone volume and a 27.6% of marrow space.

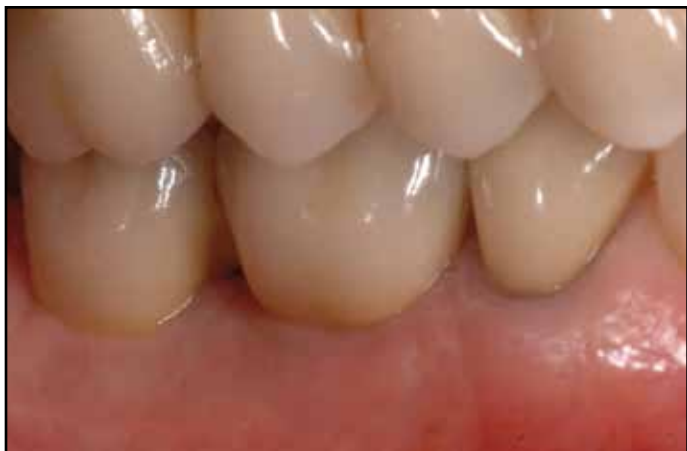

Figure 10: Case III - Clinical view of completed case at a 4-year follow up. (Prosthodontist: Dr. Nicola Perakis).




Figure 11: Case III - Histology of the regenerated area - Gomori staining. A DBM particle (center of the picture in blue) is well encased in newly formed bone. The green color indicates areas of recent bone apposition.

CASE 4

A non smoking female patient 42 years old, in good general health and with no allergies, presented with the chief complaint of restoring the masticatory function in the fourth quadrant (Figure 12). Implant therapy was suggested to restore the missing dental elements. She was sent for a CBCT scan and the ridge appeared moderately resorbed in the bucco-lingual dimension. Osseous regeneration was then performed. Healing was uncomplicated and the patient was referred for a second CBCT scan five months after surgery. The ridge morphology in the radiograph was now more favorable and two 4-mm diameter implants (Biomet 3i, Palm Beach Gardens, Florida, USA) were placed uneventfully eight months following GBR. The patient did not present problems during the healing period, and uncovering of the two fixtures was accomplished after three months. The final restorations were later delivered (Figure 13). The histologies performed in

the area of the implants in positions 30 and 31 showed a compact layer of cortical bone with underlying normal cancellous spaces and few remnants of DBM. The particles of DBM were found included in newly formed normal osseous tissue that displayed a mature lamellar organization with visible osteons and osteocytes in their lacunae. The irregular shape of a DBM particle could be suggestive of active remodeling taking place at its periphery (Figure 14). The histomorphometric evaluation of the osteotomy areas reported a mean trabecular bone volume of 56.5% with a mean marrow area of 40.8% and a remaining volume of 2.7% of graft material.

DISCUSSION

The clinical report confirms the validity of a previously described surgical approach to horizontal guided bone regeneration.²⁵ For all of the presented patients, the regenerative technique improved the morphology of the edentulous ridge, thus allowing for a more ideal

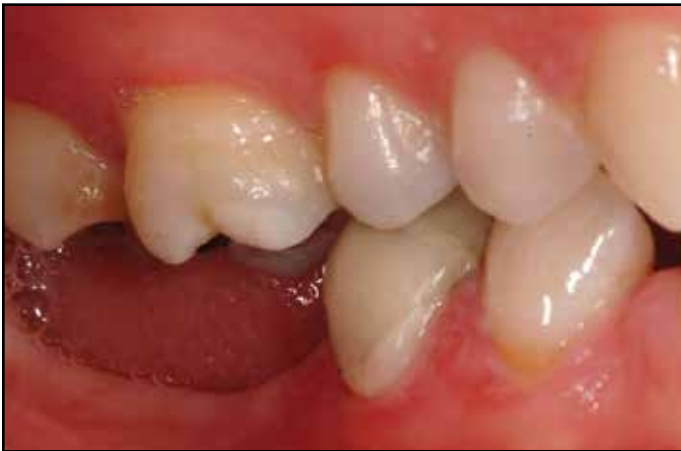

Figure 12: Case IV - Clinical view of preoperative situation.

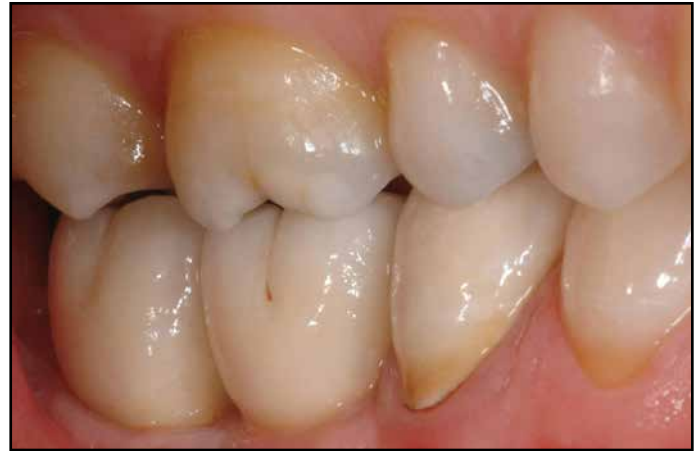

Figure 13: Case IV - Clinical view of completed case. (Prosthetics by Dr Alessandro Cantagalli)

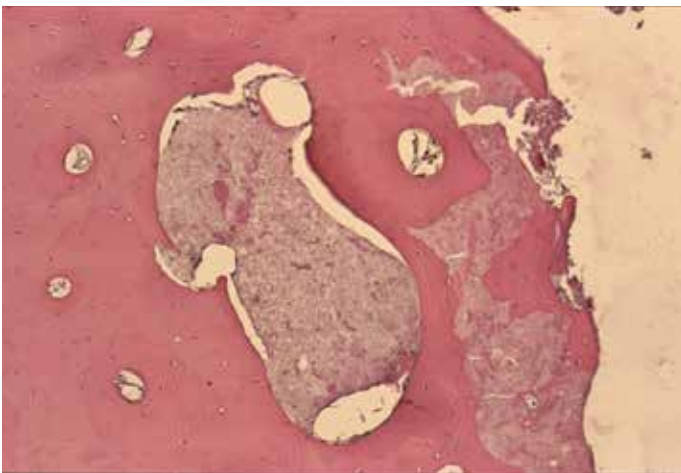


Figure 14: Case IV - Histology of the regenerated area - Hematoxylin and eosin stain. DBM particles encased in mature lamellar bone; the irregular shape of the DBM particle (left side of the picture) may be suggesting of active remodeling.

implant placement. Better positioning of the fixtures allowed for final restorations with better emergence profiles, and as a result, the overall harmony of the implant-supported prosthesis in relation to the adjacent and opposing dental elements was enhanced. While it might be argued that the esthetic benefit was super-

fluous in the non-esthetic areas, it is easy to appreciate how a better emergence profile may improve the ease of both home and professional hygiene maintenance procedures, thus reducing the potential for future biological complications.²⁶ A more favorable implant location under the occlusal table, and a better orientation of the fixtures could also be obtained, allowing for a reduction of negative bending moments that could cause over time several biomechanical complications.²⁷

The adopted regenerative technique presents several advantages when compared with other surgical procedures designed to rebuild lost osseous structure.^{4-17,23,24} A significant portion of the graft material was constituted by autogenous bone of intra-membranous origin, that could be obtained “on site” without invading more remote donor areas. Additionally, according to the proposed technique, the demineralized bone matrix was mainly, if not only, utilized to fill the voids left by the trephining action so that the procured autogenous material could not fall back in to the donor

sites. In doing so we lightly packed the osteoconductive and osteoinductive DBM material^{3,23,24} within the confines of circumferential non-through and through defects with a diameter of 3.2 mm, which were already below the critical size defect dimension,²⁸ hence having a high spontaneous regenerative potential that could be further improved by the DBM. At the same time the gold standard autogenous graft, characterized not only by its osteoconductivity and osteoinductivity but also by its osteogenic properties,^{23,29} was placed where most needed on the atrophic side of the ridge, where the regenerative potential is reduced. The grafted area was then protected by the use of a resorbable collagen membrane that had previously been reported to be equally effective as an e-PTFE non-resorbable barrier.²⁰ The obvious advantage in using a biodegradable type of material is related to the non-necessary surgical removal of the barrier and furthermore to the significantly reduced risk of post-operative infection in case of membrane exposure.²⁰ The manufacturer's claims regarding the improved resorption profile of the Ossix membrane (Colbar R&D Ltd., Ramat Hasharon, Israel), already confirmed by another case series,²¹ was verified in two of the four reported cases, where the membrane could still be seen after 5 and 9 months from the material implantation. It has been the experience of the authors that the biodegradation of this newly patented crossed linked collagenous material is indeed slower than others biodegradable membranes therefore allowing for a longer barrier effect.

The bovine origin of the collagen used in the manufacturing of the Ossix membrane has been abandoned in favor of porcine collagen with the

launch of the Ossix Plus material (Colbar R&D Ltd., Ramat Hasharon, Israel), for which complete ossification of the membrane has been reported in a dog study by others.³⁰ The same phenomenon was clinically found by the authors in the second patient here presented. To our knowledge this is the first human report of such an event in a GBR procedure. Unfortunately in spite of the positive results reported by the authors and others^{20,21,22,25,30} on the use of the Ossix and Ossix Plus barrier, the production of this material has been recently discontinued.

The histologies obtained in the implant osteotomies showed no signs of inflammation thus supporting the good compatibility of the implanted biomaterials. In general the test areas were more cancellous than the control sections, with bone displaying a higher cellularity when compared to the controls, suggesting a more recent origin of the tissue. The bone in the regenerated areas was already organized in a lamellar fashion with few dispersed primary osteons indicating a young but already well-structured tissue; signs of new bone formation with osteoblasts actively forming osseous matrix could be seen on the endosteal surfaces. Several DBM particles were nicely encased by newly generated bone confirming the well-known osteoconductive property of the allograft. The shape of some particles was quite jagged probably as a result of the slow remodeling of the material. The histomorphometric evaluation done on all the histological test samples collected was averaged out giving an overall mean value of trabecular bone volume of 50.9% (SD \pm 6.1%); the overall mean volume of marrow was equal to 43.9% (SD \pm 8.1%), while the remaining mean DBM graft material was 5%

(SD ± 3.4%) . For the control specimens the figure were: mean TBV of 64.5% (SD ± 7%), mean marrow space volume equal to 35.5% (SD ± 7%).

In conclusion the clinical, radiographic and histological results presented in this series of cases support the use of the previously reported modified guided bone regenerative procedure²⁵ as a valid method to achieve improved implant placement with a more satisfying prosthetic outcome. ●

Correspondence:
 Dr. Diego Capri
 COBE DENTAL – Via Bazzanese 32/4,
 40030 Casalecchio di Reno (Bologna-ITALY)
 Telephone 011-39-0516132796
 Fax 011-39-0516137011
 cobedental@gmail.com

Disclosure

The authors report no conflicts of interest.

References

1. Smukler H, Castellucci F, Capri D. The role of the implant housing in obtaining aesthetics: Generation of peri-implant gingivae and papillae-Part I. *Pract Proced Aesthet Dent* 2003; 15: 141-149.
2. Schropp L, Wenzel A, Kostopoulos L, Karring T. Bone healing and soft tissue contour changes following single-tooth extraction: A clinical and radiographic 12-month prospective study. *Int J Periodontics Restorative Dent*. 2003 Aug; 23(4):313-23.
3. Brugnami F, Then PR, Moroi H, Kabani S, Leone CW. GBR in human extraction sockets and ridge defects prior to implant placement: clinical results and histologic evidence of osteoblastic and osteoclastic activities in DFDBA. *Int J Periodontics Restorative Dent* 1999; 19: 259-267.
4. Nyman S, Lang NP, Buser D, Bragger U. Bone regeneration adjacent to titanium dental implants using guided tissue regeneration: a report of two cases. *Int J Oral Maxillofac Implants*. 1990; 5: 9-14.
5. Simion M, Trisi P, Piattelli A. Vertical ridge augmentation using a membrane technique associated with osseointegrated implants. *Int J Periodontics Restorative Dent* 1994; 14: 496-511.
6. Nevins M, Mellonig JT. The advantages of localized ridge augmentation prior to implant placement: A staged event. *Int J Periodontics Restorative Dent* 1994; 14: 96-111.
7. Misch CE, Dietsch F. Endosteal implants and iliac crest grafts to restore severely resorbed totally edentulous maxillae--a retrospective study. *J Oral Implantol*. 1994; 20(2):100-110.
8. Dahlin C, Lekholm U, Becker W, Becker B, Higuchi K, Callens A, van Steenberghe D. Treatment of fenestration and dehiscence bone defects around oral implants using the guided tissue regeneration technique: a prospective multicenter study. *Int J Oral Maxillofac Implants* 1995; 10: 312-8.
9. Misch CM. Ridge augmentation using mandibular ramus bone grafts for the placement of dental implants: presentation of a technique. *Pract Periodontics Aesthet Dent* 1996; 8: 127-35.
10. Misch CM. Comparison of intraoral donor sites for onlay grafting prior to implant placement. *Int J Oral Maxillofac Implants*. 1997 Nov-Dec; 12(6):767-76.
11. Hunt DR, Jovanovic SA. Autogenous bone harvesting: a chin graft technique for particulate and monocortical bone blocks. *Int J Periodontics Restorative Dent* 1999; 19: 165-73.
12. Misch CM. Use of the mandibular ramus as a donor site for onlay bone grafting. *J Oral Implantol*. 2000; 26(1):42-9.
13. Joshi A, Kostakis GC. An investigation of post-operative morbidity following iliac crest graft harvesting. *Br Dent J* 2004; 196: 167-71
14. Raghoebar GM, Louwse C, Kalk WW, Vissink A. Morbidity of chin bone harvesting. *Clin Oral Implants Res* 2001; 12: 503-7.
15. Chiapasco M, Romeo E, Casentini P, Rimondini L. Alveolar distraction osteogenesis versus vertical guided bone regeneration for the correction of vertically deficient edentulous ridges: a 1-3 year prospective study on humans. *Clin Oral Implants Res* 2004; 15(1): 82-95.
16. Linde A, Alberius P, Dahlin C, Bjurstram K, Sundin Y. Osteopromotion: a soft-tissue exclusion principle using a membrane for bone healing and bone neogenesis. *J Periodontol*. 1993; 64 (11 Suppl): 1116-28.
17. Carpio L, Loza J, Lynch S, Genco R. Guided bone regeneration around endosseous implants with anorganic bovine bone mineral. A randomized controlled trial comparing bioabsorbable versus non-resorbable barriers. *J Periodontol* 2000; 71 :1743-9.
18. Simion M, Baldoni M, Rossi P, Zaffe D. A comparative study of the effectiveness of e-PTFE membranes with and without early exposure during the healing period. *Int J Periodontics Restorative Dent* 1994; 14: 166-180.
19. Oh TJ, Meraw SJ, Lee EJ, Giannobile WV, Wang HL. Comparative analysis of collagen membranes for the treatment of implant dehiscence defects. *Clin Oral Implants Res* 2003; 14(1): 80-90.
20. Moses O, Pitaru S, Artzi Z, Nemcovsky CE. Healing of dehiscence-type defects in implants placed together with different barrier membranes: a comparative clinical study. *Clin Oral Implant Res* 2005; 16(2): 210-9.
21. Friedman A, Strietzel FP, Meretzki B, Pitaru S, Bernimoulin JP. Observation of a new collagen barrier membrane in 16 consecutively treated patients. Clinical and histological findings. *J Periodontol* 2001; 72: 1616-1623.
22. Friedmann A, Strietzel FP, Meretzki B, Pitaru S, Bernimoulin JP. Histological assessment of augmented jaw bone utilizing a new collagen barrier membrane compared to a standard barrier membrane to protect a granular bone substitute material. *Clin Oral Implants Res* 2002 Dec; 13(6):587-94.
23. Simion M, Dahlin C, Trisi P, Piattelli A. Qualitative and quantitative comparative study on different filling materials used in bone tissue regeneration: a controlled clinical study. *Int J Periodontics Restorative Dent* 1994; 14: 198-215.
24. Smukler H, Landi L, Setayesh R. Histomorphometric evaluation of extraction sockets and deficient alveolar ridges treated with allograft and barrier membrane: a pilot study. *Int J Oral Maxillofac Implants* 1999; 14: 407-16.
25. Smukler H, Capri D, Landi L. Harvesting bone in the recipient site for ridge augmentation. *Int J Periodontics Restorative Dent* 2008; 28(4): 411-419.
26. Karoussis IK, Salvi GE, Heitz-Mayfield LJ, Bragger U, Hammerle CH, Lang NP. Long-term implant prognosis in patients with and without a history of chronic periodontitis: a 10-year prospective cohort study of the ITI® dental implant system. *Clin. Oral Implants Res* 2003; 14: 329 – 339.
27. Pjetursson BE, Tan K, Lang NP, Bragger U, Egger M, Zwahlen M. A systematic review of the survival and complication rates of fixed partial dentures (FPDs) after an observation period of at least 5 years. *Clin Oral Implants Res* 2004; 15(6): 625-642.
28. Thorwarth M, Schultze-Mosgau S, Kessler P, Wiltfang J, Schlegel KA. Bone regeneration in osseous defects using a resorbable nanoparticulate hydroxyapatite. *J Oral Maxillofac Surg* 2005; 63(11): 1626-33.
29. Gross JS. Bone grafting materials for dental applications: a practical guide. *Compend Contin Educ Dent* 1997; 18(10): 1013-8, 1020-2, 1024.
30. Zubery Y, Goldlust A, Alves A, Nir E. Ossification of a novel cross-linked porcine collagen barrier in guided bone regeneration in dogs. *J Periodontol* 2007; 78: 112-121.