

Staged Removal of Horizontally Impacted Third Molars to Reduce Risk of Inferior Alveolar Nerve Injury

Luca Landi, DDS,* Paolo Francesco Manicone, DDS,†
Stefano Piccinelli, DDS,‡ Alessandro Raia, DDS, PhD,§ and
Roberto Raia, DDS||

Damage to the inferior alveolar nerve (IAN) during third molar extraction is a major concern for patients and clinicians. A wide range of the incidence of temporary and permanent neurologic disturbances of the IAN as a consequence of mandibular impacted third molar extraction has been reported in the literature.¹ The incidence of IAN injury reported in the literature ranges from 1.3% to 5.3%.²⁻⁵ The risk of this complication depends mainly on the position of the impacted tooth in relation to the inferior alveolar canal.⁶ To reduce this risk, several approaches have been proposed. Some authors advocated orthodontic-assisted extraction of the impacted mandibular third molars.⁷⁻⁹ Others introduced partial odontectomy, that is, the surgical removal of the anatomic crown leaving the roots in place.¹⁰⁻¹² This case report describes a novel approach to the extraction of horizontally and mesially inclined impacted third molars with the root apexes in close contact with the IAN.

Report of a Case

A 28-year-old female patient, in good general health, was referred for bilateral extraction of the mandibular third molars for orthodontic reasons. The panoramic radiograph

(Fig 1) showed the mandibular third molars in horizontal impaction with root apexes superimposed to the IAN. The computed tomography scan confirmed the intimate relationship between the teeth and the IAN (Fig 2). Therefore both extractions had an elevated risk of neurologic disturbances. Several options were proposed to the patient, such as orthodontic-assisted extraction, second molar extraction and orthodontic recovery of the third molar, and intentional odontectomy. In addition, the no-treatment option was discussed. A staged surgical extraction was then proposed and accepted by the patient, who signed an informed consent form.

The 2 impacted molars were approached separately. The first tooth to be treated was the right mandibular third molar. In brief, with the patient under local anesthesia (articaine with epinephrine, 1:100,000) (Ubistesin; 3M ESPE, Seefeld, Germany), a hockey stick-shaped full-thickness flap was designed and raised to expose the impacted tooth. Osteotomy was carried out with carbide and diamond burs to obtain access to the tooth. Then, by use of a fissure bur, the anatomic crown was partially sectioned and the sectioned part removed. Care was taken to avoid pulp exposure. At this point, the distance between the distal aspect of the second molar and the mesial aspect of the sectioned impacted tooth was measured and recorded to monitor the degree of migration of the right mandibular third molar. Before closing, a periapical radiograph of the area was obtained as a reference (Fig 3). Single interrupted resorbable No. 5-0 sutures (Vicryl; Ethicon, Somerville, NJ) were used to close the flap. An anti-inflammatory drug (400 mg of ibuprofen 3 times daily) was administered at the end of the procedure for pain management. The patient was instructed to rinse twice a day for the rest of the week with 0.2% chlorhexidine. Healing was uneventful, and a week later, the sutures were removed. A monthly check-up was scheduled for the first 3 months.

At the 3-month visit, a new periapical radiograph was obtained (Fig 4). The right mandibular third molar had already reached the distal aspect of the second molar. However, radiographically, there was not enough clearance between the alveolar canal and the mesial root apex yet. We decided to perform a second sectioning of the third molar to allow further migration. With the patient under local anesthesia, a limited flap was raised without a vertical releasing incision and a further portion of the residual crown was cut away. Pulpotomy was necessary because pulp exposure was not avoidable this time. The chamber access was then sealed with a temporary filling material (Coltosol; Coltene Whaledent, Langenau, Germany). The flap was

*Private Practice, Studio di Odontoiatria Ricostruttiva, Rome, Italy.

†Private Practice, Studio di Odontoiatria Ricostruttiva, Rome, Italy; and Assistant Professor, Department of Prosthodontics, Catholic University of Sacred Heart, Rome, Italy.

‡Private Practice, Studio di Odontoiatria Ricostruttiva, Rome, Italy.

§Private Practice, Studio di Odontoiatria Ricostruttiva, Rome, Italy; and PhD Resident, Department of Orthodontics, Catholic University of Sacred Heart, Rome, Italy.

||Private Practice, Studio di Odontoiatria Ricostruttiva, Rome, Italy.

Address correspondence and reprint requests to Dr Landi: Via della Balduina 114, 00136 Rome, Italy; e-mail: studio.ric@tin.it

© 2010 American Association of Oral and Maxillofacial Surgeons

0278-2391/10/6802-0032\$36.00/0

doi:10.1016/j.joms.2009.07.038

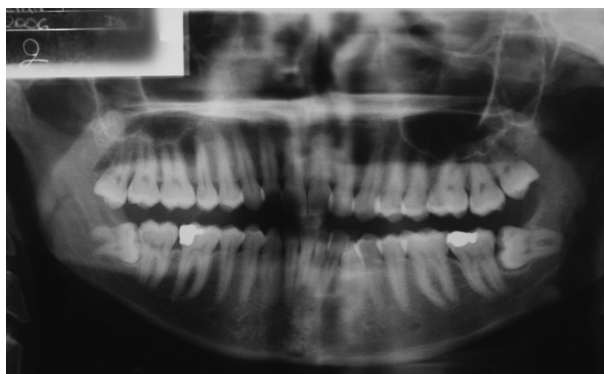

FIGURE 1. Panoramic radiograph at initial consultation. The mandibular third molars are mesially impacted with the roots close to the alveolar canal.

Landi et al. Avoiding Inferior Alveolar Nerve Damage. J Oral Maxillofac Surg 2010.

then sutured back, and a radiograph was obtained (Fig 5). A week later, the patient returned for suture removal. Healing was again uneventful. Two months later, another periapical radiograph was obtained, and at that time, the right mandibular third molar had reached a safe position with respect

to the IAN (Fig 6). A riskless surgical extraction was then scheduled.

By use of the same technique described for the first surgery, the tooth was exposed. Because of migration movement, the tooth was highly mobile and no further osteotomy was necessary to elevate and extract it. The flap was then sutured back, and the same postoperative management protocol was prescribed. Again, healing was uneventful, and the patient recovered well from the procedure. At this point, the same approach was used to manage the left mandibular third molar. This time, only 1 sectioning was required (Fig 7), and 3 months after the first surgery, the tooth migrated mesially (Figs 8, 9) and was successfully extracted. No postoperative complications or signs of paresthesia of the IAN were recorded.

Discussion

Neurologic disturbance of the IAN after surgical removal of an impacted third molar is a serious complication. Although the incidence of such a complication is relatively low, its frequency increases when the roots of the impacted tooth are located near the nerve bundle.⁶ Once a clear indication for extraction

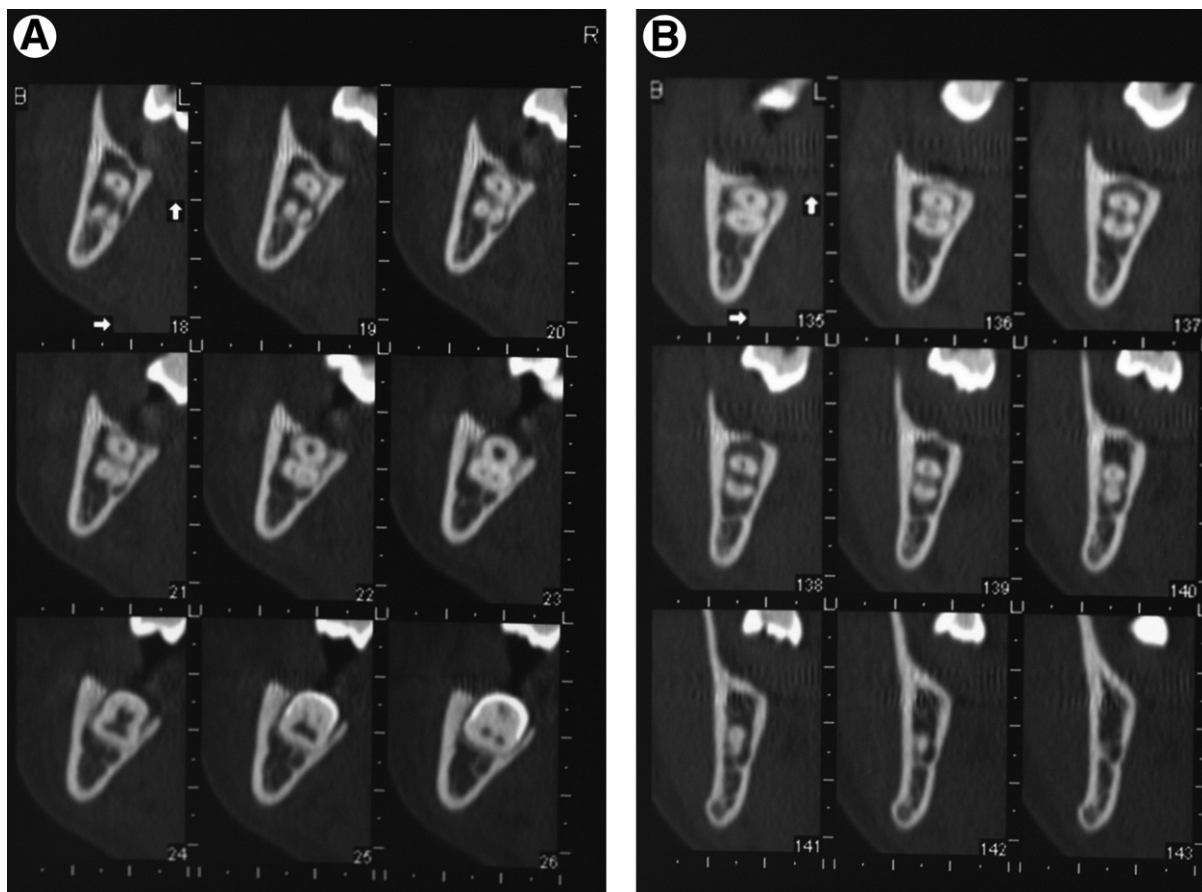


FIGURE 2. A, B, Computed tomography scan of third molar area. The tight relationship of the roots with the nerve bundle is clearly visible. Extraction would result in a high risk of nerve injury.

Landi et al. Avoiding Inferior Alveolar Nerve Damage. J Oral Maxillofac Surg 2010.

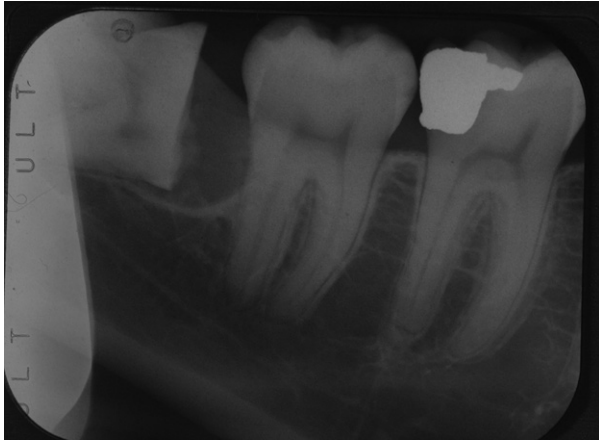


FIGURE 3. Postoperative radiograph after the right mandibular third molar was surgically sectioned. The space distal to the second molar would allow mesial migration of the impacted tooth.

Landi et al. Avoiding Inferior Alveolar Nerve Damage. J Oral Maxillofac Surg 2010.

has been made, the clinician should devise a strategy to reduce the risk of this complication. Checchi and coworkers^{7,8} presented an interesting approach by using an orthodontic appliance to move the third molar away from the IAN. They reported on a case of a deeply vertically impacted third molar in need of extraction.⁸ Five months after active orthodontic movement and 3 months after stabilization, they were able to extract the tooth without any neurologic consequences. The 3-month stabilization period after active extrusion was chosen to allow mineralization of the newly formed tissue to occur. This process would have improved the periodontal attachment level at the distal aspect of the second molar that was severely affected by the presence of the impacted tooth. How-

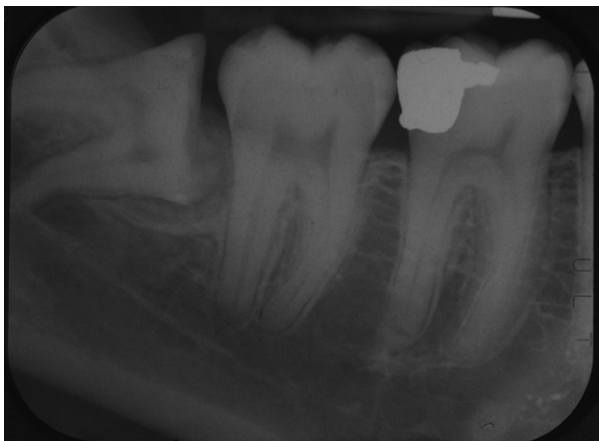

FIGURE 4. Three months after odontectomy. The third molar moved mesially. However, the mesial root was still in contact with the alveolar canal. A second sectioning was required.

Landi et al. Avoiding Inferior Alveolar Nerve Damage. J Oral Maxillofac Surg 2010.

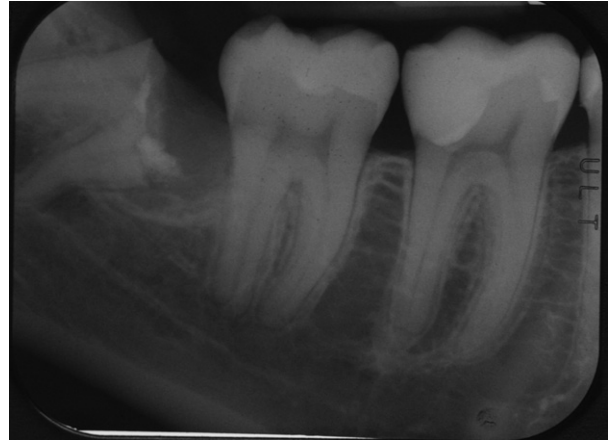

FIGURE 5. Postoperative radiograph after second sectioning of the right mandibular third molar. A pulpotomy has been performed. More space was created distal to the right mandibular second molar to allow further migration.

Landi et al. Avoiding Inferior Alveolar Nerve Damage. J Oral Maxillofac Surg 2010.

ever, the authors mentioned that this technique, though very effective in reducing the risk of paresthesia, is time-consuming, is more expensive, and may not be well tolerated by the patient. The orthodontic device is applied in an area of the mouth that is very difficult to access, and it may cause compression and ulceration of the neighboring tissues with a certain degree of discomfort. Our approach aimed to provide adequate space distal to the second molar to allow spontaneous third molar eruption to displace the roots away from the neurovascular bundle. There is evidence in young adults that 26% to 35% of unerupted mandibular third molars may change their position over time and reach the occlusal plane.^{10,11} This residual erupting activity of impacted third mo-

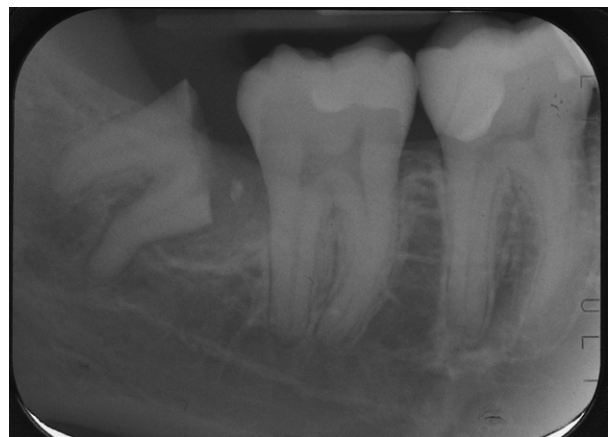

FIGURE 6. Periapical radiograph obtained 2 months after second sectioning. At that time, the roots were away from the alveolar canal, and a riskless extraction could be scheduled.

Landi et al. Avoiding Inferior Alveolar Nerve Damage. J Oral Maxillofac Surg 2010.

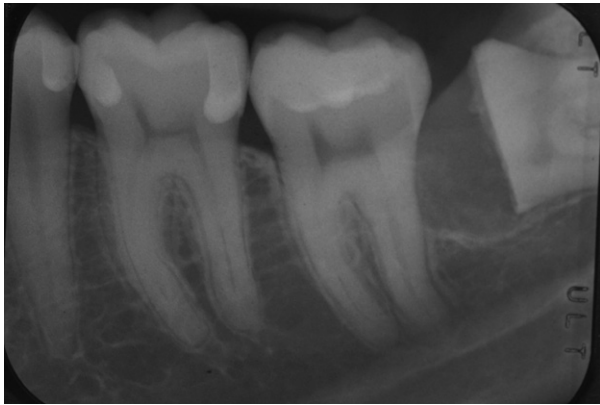

FIGURE 7. Radiograph showing the left mandibular third molar after odontectomy.

Landi et al. Avoiding Inferior Alveolar Nerve Damage. J Oral Maxillofac Surg 2010.

lars seems to be influenced by the pattern of impaction, because only 3% of horizontally or mesially angulated impacted third molars, with an angle of impaction greater than 35°, may spontaneously erupt compared with more than 30% of vertically positioned third molars.¹⁰ Therefore it may be speculated that once space is provided mesial to the third molar, further migration of the tooth may be possible. This novel technique consists of a first surgical approach similar to the one adopted to extract impacted third molars. The amount of sectioning should take into account several factors: 1) tooth position, 2) degree of mesial shift desired to move the roots away from the nerve, and 3) pulp chamber anatomy. Although a generous amount of sectioning is desirable, every effort should be made, at least during the first cut, not

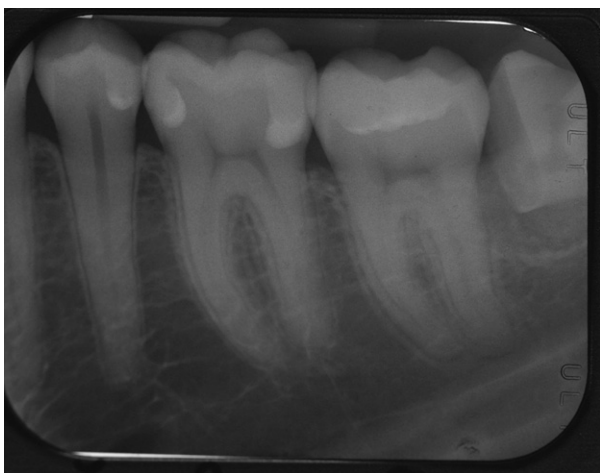

FIGURE 8. Three months after odontectomy, the left mandibular third molar reached the distal aspect of the second molar. On this radiograph, it is not possible to evaluate the new relationship between the roots and the IAN.

Landi et al. Avoiding Inferior Alveolar Nerve Damage. J Oral Maxillofac Surg 2010.

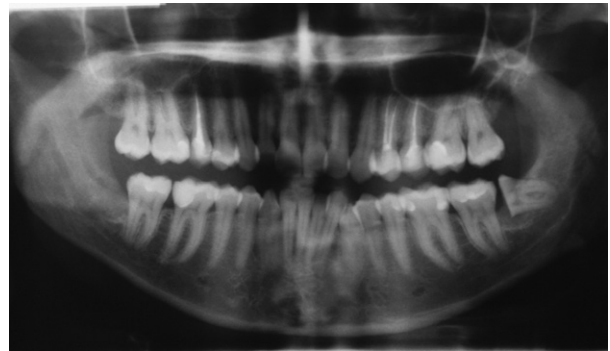


FIGURE 9. Panoramic radiograph showing clearance between the left mandibular third molar and alveolar canal after mesial migration. Extraction could be carried out with a reduced risk of paresthesia. The radiograph also shows good healing of the right mandibular third molar extraction site.

Landi et al. Avoiding Inferior Alveolar Nerve Damage. J Oral Maxillofac Surg 2010.

to interfere with tooth vitality. In case of accidental pulp exposure, a pulpotomy may be done to minimize the risk of postoperative pain and discomfort. It may be speculated that this approach should be primarily used whenever the following features are present: 1) in the case of horizontal or mesially inclined third molar impaction, 2) when radiographic evidence of the proximity of the third molar roots to the IAN is confirmed on a computed tomography scan, 3) when the crown of the third molar is in contact with the distal aspect of the second molar, 4) if an established pathologic process is detectable in the area of impaction (caries or deep periodontal defect) that indicates the need for third molar removal, 5) preferably (but not exclusively) in young patients, and 6) whenever orthodontic-assisted extraction may be very complex to apply. This approach may also reduce chair time and cost compared with the orthodontic-assisted technique while improving patient comfort. Another advantage may be in the case of tooth ankylosis. In that instance, orthodontic therapy may fail to move the appropriate tooth while causing undesired movement of the anchoring teeth. By use of this technique, once the tooth is sectioned and no movement can be detected, the residual tooth may be left in place as for an intentional odontectomy¹²⁻¹⁴ provided that no signs and symptoms of pathology occurred. The use of 2 surgical procedures may be considered a potential drawback of this approach. Furthermore, a second sectioning of the impacted tooth may be indicated in cases in which further migration is required, leading to a total of 3 surgical, albeit minor, procedures. It is interesting to note that the second sectioning, to allow further migration of the right mandibular third molar, required local anesthesia and a minimally invasive surgical approach that may be comparable in terms of discomfort to an

endodontic or restorative procedure. In addition, post-operative tooth hypersensitivity induced by the odontectomy should be taken into consideration as a potential complication. This case report describes a novel approach to the extraction of horizontally impacted mandibular third molars that have a high risk of IAN paresthesia. This staged approach may be promising, and further investigations may be warranted to evaluate its efficacy in a large sample of patients.

References

1. Libersa P, Savignat M, Tonnel A: Neurosensory disturbances of the inferior alveolar nerve: A retrospective study of complaints in a 10-year period. *J Oral Maxillofac Surg* 65:1486, 2007
2. Bataineh AB: Sensory nerve impairment following mandibular third molar surgery. *J Oral Maxillofac Surg* 59:1012, 2001
3. Kipp DP, Goldstein BH, Weiss WW: Dysesthesia after mandibular third molar surgery: A retrospective study and analysis of 1,377 surgical procedures. *J Am Dent Assoc* 100:185, 1980
4. Goldberg MH, Nemerich AN, Marco WP: Complications after mandibular third molar surgery: A statistical analysis of 500 consecutive procedures in private practice. *J Am Dent Assoc* 111:277, 1985
5. Smith AC, Barry SE, Chiong AY, et al: Inferior alveolar nerve damage following removal of mandibular third molar teeth: A prospective study using panoramic radiography. *Aust Dent J* 42:149, 1997
6. Bui CH, Seldin EB, Dodson DB: Types, frequencies and risk factors for complications after third molar extraction. *J Oral Maxillofac Surg* 61:1379, 2003
7. Checchi L, Bonetti GA, Pelliccioni GA: Removing of high-risk impacted mandibular third molar. A surgical orthodontic approach. *J Am Dent Assoc* 127:1214, 1996
8. Bonetti GA, Bendandi M, Laino L, et al: Orthodontic extraction: Riskless extraction of impacted lower third molars close to the mandibular canal. *J Oral Maxillofac Surg* 65:2580, 2007
9. Hirsch A, Shteiman S, Boyan BD, et al: Use of orthodontic treatment as an aid to third molar extraction: A method for prevention of mandibular nerve injury and improved periodontal status. *J Periodontol* 74:887, 2003
10. Phillips C, Norman J, Jaskolka M, et al: Changes over time in position and periodontal probing status of retained third molars. *J Oral Maxillofac Surg* 65:2011, 2007
11. Nance P, White R Jr, Offenbacher S, et al: Change in third molar angulation and position in young adults and follow-up periodontal pathology. *J Oral Maxillofac Surg* 64:424, 2006
12. O'Riordan BC: Coronectomy (intentional partial odontectomy of lower third molars). *Oral Surg Oral Med Oral Pathol Oral Radiol Endod* 98:274, 2004
13. Pogrel MA, Lee JS, Muff DF: Coronectomy: A technique to protect the inferior alveolar nerve. *J Oral Maxillofac Surg* 62:1447, 2004
14. Renton T, Hankins M, Sproate C, et al: A randomized controlled clinical trial to compare the incidence of injury to the inferior alveolar nerve as a result of coronectomy and removal of mandibular third molar. *Br J Oral Maxillofac Surg* 43:7, 2005

J Oral Maxillofac Surg
68:446-451, 2010

Central Adenoid Cystic Carcinoma of the Mandible With Multiple Bone Metastases: Case Report

Takamitsu Mano, DDS, PhD, Noriko Wada, DDS,†
Kenichiro Uchida, DDS, PhD,‡ Yukoh Muraki, DDS, PhD,§
Hitoshi Nagatsuka, DDS, PhD,|| and
Yoshiya Ueyama, DDS, PhD¶*

Adenoid cystic carcinoma (ACC) is a malignant epithelial neoplasm originating in the salivary gland. ACC arising centrally within the mandible is extremely rare, with only 17 previously reported cases.¹⁻¹⁷ ACC

typically presents with slow, indolent growth, but there is a high incidence of local recurrence and metastasis, which results in the low long-term survival rate. A recent case of ACC of the mandible with

*Associate Professor, Department of Oral and Maxillofacial Surgery, Yamaguchi University Graduate School of Medicine, Yamaguchi, Japan.

†Resident, Department of Oral and Maxillofacial Surgery, Yamaguchi University Graduate School of Medicine, Yamaguchi, Japan.

‡Assistant, Department of Oral and Maxillofacial Surgery, Yamaguchi University Graduate School of Medicine, Yamaguchi, Japan.

§Chief, Dentistry and Oral Surgery, Tokuyama Central Hospital, Yamaguchi, Japan.

||Professor, Department of Oral Pathology and Medicine, Graduate School of Medicine, Dentistry and Pharmaceutical Sciences, Okayama

University, Okayama, Japan.

¶Professor, Department of Oral and Maxillofacial Surgery, Yamaguchi University Graduate School of Medicine, Yamaguchi, Japan.

Address correspondence and reprint requests to Dr Mano: Department of Oral and Maxillofacial Surgery, Yamaguchi University School of Medicine, 1-1-1 Minamikogushi Ube, Yamaguchi 755-8505, Japan; e-mail: tmano@yamaguchi-u.ac.jp

© 2010 American Association of Oral and Maxillofacial Surgeons
0278-2391/10/6802-0033\$36.00/0

doi:10.1016/j.joms.2009.07.025